European Review for Medical and Pharmacological Sciences 2012; 16: 414-417

Upper eyelid necrosis and reconstruction after spider byte: case report and review of the literature

D. RIBUFFO, F. SERRATORE, M. FAMIGLIETTI, M. GRECO***, F. FOIS*, L. ATZORI**, M. PAU**, N. ASTE**

Section of Plastic Surgery, Department of Surgery, Cagliari University Hospital, Monserrato, Cagliari (Italy)
*Life Sciences Department, Section of Animal Biology, Cagliari University, Cagliari (Italy)
**Dermatology Clinic, Cagliari University, Cagliari (Italy)
***Unit of Plastic Surgery, University of Catanzaro, Catanzaro (Italy)

Abstract. – Spider bites are not very common, especially in the Mediterranean area, and those affecting the ocular-palpebral region involving reconstructive surgery are particularly rare. In May 2010, the case of a Caucasian 24-year-old female patient was brought to the attention of the Dermatology Department, University of Cagliari, Italy. The patient reported she woke up feeling an intense pain with itching and that also she had noticed a spider of an unknown species on her bed. The dermatosis had affected the right orbital region, where there was a considerable red and violet erythema and a hard edema, not foldable. When the necrosis appeared the patient was treated at the Plastic Surgery Unit where she underwent a reconstruction of the eyelid with a full thickness skin graft from the retroauricular area. The post-operative course was regular with a perfect in-take of the skin graft. When the patient was discharged she was sent to an Entomological University Centre to identify the spider species and the possible venom which caused the skin lesion. The spider which caused the injury has been a Loxosceles rufescens (Dufour, 1820). Loxoscelism is a necrotic arachnoidism caused by the poisonous bite of spiders belonging to the Loxosceles species. It is very important to identify what sort of lesion it is and to treat it in a combined way in order to choose the proper timing for surgery to avoid damages to the eyelid functioning.

Key Words:

Eyelid necrosis, Spider byte, Upper eyelid reconstruction.

Introduction

Spider bites are not very common, especially in the Mediterranean area, and those affecting the ocular-palpebral region involving reconstructive surgery are particularly rare[1-3]. It is not always easy to identify the spider species and, therefore, to make a diagnosis, in order to treat the lesions properly and timely as to avoid damages to the affected area.

Here we report the case of a 24-year-old patient treated by a team of doctors, firstly at the Department of Dermatology and then at the Plastic Surgery Unit, University of Cagliari Hospital, Italy.

Case Report

In May 2010, the case of a Caucasian 24-year-old female patient was brought to the attention of the Dermatology Department. She had an edema on the right upper eyelid and a skin rash on the homolateral cheek region. The area was extremely painful and tender (Figure 1).

The patient reported she woke up feeling an intense pain with itching and that also she had noticed a spider of an unknown species between the sheets of her bed.

Four days later she was admitted as an emergency patient to the Dermatology Department. At the beginning the patient woke up feeling a pressing pain on the right upper eyelid, accompanied by an erythema and a soft edema, which got worse gradually. The day after the alleged bite, the patient was examined at the Opthalmologic Emergency Unit where the orbit computed tomography (CT) scan excluded troubles of the bulb of the eye and of the retrobulbar fat, but confirmed swelling of the soft tissue of the anterolateral region of the orbit which also affected the cheek region. Doctors prescribed her antibi-

Corresponding Author: Francesco Serratore, MD; e-mail: serratorefrancesco@yahoo.it

Figure 1. The patient on admission in Dermatology.

otics (azithromycin dihydrate 1 cp/die for 3 days). Considered the poor clinical response, they substituted it with amoxicillin trihdrate/potassium clavulanate, 1 g twice a day. This treatment was suspended as a widespread maculo-papular rash appeared accompanied by moderate itching, which was considered an adverse drug reaction. As the dermatitis worsened, the patient was admitted to the Dermatology centre where she was treated with cortisones (methylprednisolone 30 mg/die, to be scaled down), antihistamines (loratadine 1 cp/die, chlorphenamine maleate 1 phial/die), antibiotics (Doxycycline Hyclate 100 mg/die 1 cp twice a day). When she was hospitalized, the dermatosis had affected the right orbital region, where there was a considerable red and violet erythema and a hard edema, not foldable, with a smooth, shining surface and blue and violet discoloration bruise-like area with an irregular rhomboidal shape in the middle. The palpebral erythematous and edematous plaque had not defined borders, nor did it show signs of an advancing border and it appeared connected to the erythema and the edema of the homolateral lower palpebral region and cheekbone region. Contralaterally, there was a soft erythema and edema of the periorbital region. In addition, there were lymphangitis striae which stretched over the right zygomatic region to the right sub-mandibular region. Also a right sub-mandibular and neck lymphadenopathy was reported. The rest of the cutaneous surface was covered in a pink-red spotted scarlatina-form rash, hands and feet included. There was no fever. The lymphangitic reaction and the widespread erythematous rash responded to the treatment rapidly, while the central area of the erythematous-infiltrative area of the right eyelid gradually got worse, and in the following days it started to look like an adhering, dry, blackish eschar.

Later the patient was treated at the Plastic Surgery Unit. The extent of the necrotic damage was 0.8 × 0.6 inches near the right upper eyelid, and affected the anterior lamella of the eyelid, with complete loss of the skin and of the orbicularis oculi muscle. The aponeurosis of the levator palpebrae superioris muscle remained unharmed. The surrounding skin was still slightly edematous and reddened (Figure 2).

Therefore, it was decided to delay surgery for a week, when reconstruction of the eyelid was accomplished with a full thickness skin graft from the retroauricular area.

When the patient was discharged she was sent to a for Entomological University Centre to identify the spider species and the possible venom which caused the skin lesion.

Results

The post-operative course was regular with a perfect in-take of the skin graft, and there were no post-operative complications. The patient was discharged from the hospital after three days and she was prescribed an antibiotic treatment (Figure 3).

The spider which caused the injury is a *Loxosceles rufescens* (Dufour, 1820), also known as the Violin Spider.

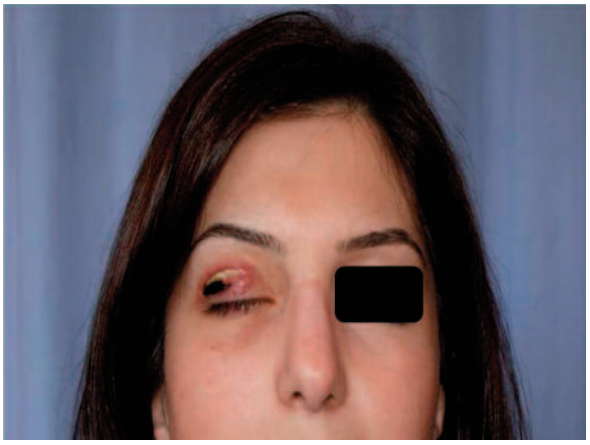

Figure 2. The patient on admission in the Department of Plastic Surgery.

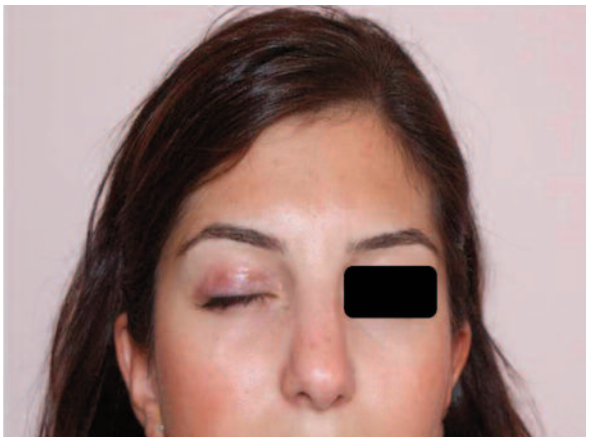

Figure 3. Four months after the surgical treatment.

Discussion

Spider bites which cause reconstructive problems are not common, especially those affecting the ocular-palpebral area. It is not possible to precisely determine the number of spider bites, as many cases remain unknown due to the fact that the spider cannot be caught.

The spider which caused this lesion belongs to the *Loxosceles* species.

Apart from Italy (islands included), this spider species can be found in Spain, Portugal, France, Netherlands, the Balkans, Greece, Balearic islands, Canary islands, Malta, Israel, Southern Russia, Northern Africa, Madagascar, Burma, China, Japan, Eastern U.S.A., Mexico, Brazil, Paraguay as well as in some islands of the Atlantic Ocean[4].

Loxoscelism is a necrotic arachnoidism caused by the poisonous bite of spiders belonging to the *Loxosceles* species. It is characterized by a localized reaction accompanied by edema and/or necrosis according to the ischaemic damage of the affected area (cutaneous type) or by general clinical symptoms which can be associated to disseminated intravascular coagulation, haemolysis and acute kidney injury (cutaneous-visceral type), which can cause the death of the patient. Cases of loxoscelism mainly caused by bites of spiders belonging to the *Loxosceles recluse* and *Loxosceles laeta* species, have been reported in South Africa, in the U.S., in South America (especially in Chile, Brazil, Uruguay and Peru) and in Israel. The mechanism involved in the physiopathology of the *Loxosceles* spider bite poisoning is complex. Its venom is composed of proteinic, non-proteinic and enzymic elements. Dermonecrotic lesions are rich in sphingomyelinase D, which causes the intra-vascular haemolysis and the neuro-toxic action on the nerve endings. In addition, some bacteria (*Clostridium* species) hidden in the chelicerae of these spiders can cause minor infections[4].

The venom has a necrotic effect on the tissues causing an ulcer which subsides in few weeks of medical treatment, but leaves visible scars. Generally speaking, the affected region presents a severe edema. Acute complications include high intra-ocular pressure[1] and problems to the respiratory system with laryngeal spasm[3].

Long-term complications include necrosis and scars which may cause corneal irritation[2].

The treatment includes systemic corticosteroids, hyperbaric oxygen[1,2] and escarectomy of the necrotic areas as well as reconstruction with local flaps[3], or grafts. Cases of high intra-ocular pressure have been treated with cantholysis and canthotomies, in order to normalize the pressure[1]. A topical and systemic antibiotic therapy could be a supporting treatment, and it may be useful to cover the eye with bandages in order to minimize the corneal irritation[2].

There is no specific lab test to identify the spider species.

There are reports of cases in which the diagnosis was made using ELISA (enzyme immuno assay), but the sensibility and specificity levels were not determined in clinical cases. *In vitro*, the ELISA has been considered specific for the *Loxosceles* species, but in vivo the necrotic and inflammatory lesions do not allow to identify the species[5].

In conclusion, the diagnosis of *Loxosceles* bite is clinical, based on the morphology of the skin lesions[6-9].

More often than not, it is not possible to make the final diagnosis as patients did not catch the spider and, therefore, the species remains unknown.

The morphology of the lesion is usually the basis to make a correct diagnosis, but when it comes to *Loxosceles* spiders is not specific[8-10] as many spider bites are similar[11-13].

In this case, the patient was sent to a specialized University Centre where they identified the spider species which, otherwise, would have been remained unknown.

It is very important to identify what sort of lesion it is and to treat it in a combined way in order to choose the proper timing for surgery to avoid damages to the eyelid functioning.

The reconstructive treatment can start only when the conditions of the affected area are ideal, that means when the infection has been treated and the necrotic damage has been demarcated, as they would not allow the take of the skin graft, as in this case. At the same time, it is necessary not to delay the surgery for too long in order to avoid functional damages which could become irreversible.

References

1) Jarvis RM, Neufeld MV, Westfall CT. Brown recluse spider bite to the eyelid. Ophthamology 2000; 107: 1492-1496.
2) Wesley RE, Ballinger WH, Close LW, Lay AM. Dapsone in the treatment of presumed brown recluse spider bite of the eyelid. Ophthalmic Surg 1985: 16: 116-117, 120.
3) Edwards JJ, Anderson RL, Wood JR. Loxoscelism of the eyelids. Arch Ophthalmol 1980; 98: 1997-2000.
4) Fois F, Piras P, Mulas A, Fois A, Uccheddu D, Deiana AM. Presenza del “ragno violino” Loxosceles rufescens in Sardegna: note bio-ecologiche, distribuzione e pericolosità. Proc XXII Congr Naz It Entomologia. Ancona, 15-18 Giugno 2009; 76.
5) Gomez HF, Miller MJ, Waggener MW, Lankford HA, Warren JS. Antigenic cross-reactivity of venoms from medically important North American Loxosceles spider species. Toxicon 2001; 39: 817-824.
6) Atkins JA, Wingo CW, Sodeman WA, Flynn JE. Necrotic arachnidism. Am J Trop Med Hyg 1958; 7: 165-184.
7) Wasserman GS, Anderson PC. Loxoscelism and necrotic arachnidism. J Toxicol Clin Toxic 1983-1984; 21: 451-472.
8) Sams HH, Dunnick CA, Smith ML, King LE Jr. Necrotic arachnidism. J Am Acad Dermatol 2001; 44: 561-573.
9) Anderson, PC. Spider bites in the United States. Dermatol Clin 1997; 15: 307-311.
10) Vetter RS. Envenomation by a spider, Agelenopsis aperta (family: Agelenidae) previously considered harmless. Ann Emerg Med 1998; 32: 739-741.
11) Rosenstein ED, Kramer N. Lyme disease misdiagnosed as a brown recluse bite [letter]. Ann Intern Med 1987; 107: 782.
12) Rees R, Campbell D, Rieger E, King LE. The diagnosis and treatment of brown recluse spider bites Ann Emerg Med 1987; 16: 945-949.
13) Moaven LD, Altman SA, Newnham AR. Sporotrichosis mimicking necrotising arachnidism. Med J Australia 1999; 171: 865-868.