

Symptomatic gastric leiomyoma mimicking giant gastric polyp: endoscopic diagnosis and removal

G. BRANDIMARTE, A. TURSI*, W. ELISEI, V. ANNUNZIATA**, E. MONARDO**

Department of Internal Medicine, Gastroenterology Division, "Cristo Re" Hospital – Rome (Italy)

*Digestive Endoscopy Unit, "Lorenzo Bonomo" Hospital – Andria (BA) (Italy)

**Division of Pathology, "Cristo Re" Hospital – Rome (Italy)

Abstract. – Gastric leiomyoma is an uncommonly found benign submucosal neoplasm which may cause hemorrhage in rare cases.

A 67-years-old patient was admitted to our attention due to two episodes of hematemesis and melena occurred in the previous two days. Esophagogastroduodenoscopy showed a giant semi-pedunculated gastric polyp (diameter of 4 centimeters) located at the distal body. A large ulcer with a clot was seen on the polyp. We treated endoscopically the giant polyp using the new two-steps-technique recently described by us for the treatment of the large pedunculated gastric and colorectal polyps, and the polypectomy was successfully performed without immediate or delayed complications. Histological evaluation of the transected polyp revealed morphology according to a gastric submucosal leiomyoma. Endoscopic control, performed one and four weeks and 12 months later, showed complete re-epithelization of the gastric mucosa, without any sign of endoscopic, endosonographic and histological recurrence of the disease.

This case report shows that our endoscopic approach may be successfully used also for giant semi-pedunculated gastric polyps.

Key Words:

Endoscopic polypectomy, Gastric polyp, Leiomyoma.

Introduction

Gastric leiomyoma is an uncommonly found benign submucosal neoplasm. Leiomyomas are often asymptomatic and they are found at autopsy or on abdominal exploration for other reasons¹. However, in some cases, these neoplasms may be symptomatic and cause compression, obstruction or hemorrhage^{2,3}.

We describe a case of symptomatic gastric leiomyoma mimicking giant gastric polyp that presented hematemesis and melena and treated with a new technique of endoscopic polypectomy.

Case Report

A 67-year-old patient was admitted to our attention due to two episodes of hematemesis and melena occurred in the previous two days. On admission the patient showed hemoglobin 10.1 g/dl (normal value: 12-15 g/dl), red cells count 2,850,000/mm³. We performed an esophagogastroduodenoscopy (Fujinon EG300 videogastroscope; Fujinon, Omiya, Japan) which showed a giant semi-pedunculated gastric polyp (diameter of 4 centimeters) located at the distal body. A large ulcer with a clot was seen on the polyp (Figure 1). We decided to treat endoscopically the giant polyp using a new technique recently described by us for the treatment of large pedunculated gastric and colorectal polyps^{4,5}.

The endoscopic removal was performed in two steps during two different endoscopic sessions.

In the first step, after injection of 8 ml of epinephrine in the base of the lesion, we placed a polypectomy snare in the same place (Disposable anchor tip poly snare, US Endoscopy Group Inc., Mentor – Ohio [USA]) as a prophylactic measure to prevent post-polypectomy bleeding (Figure 2). Then, we removed the gastroscope without removing the snare after its dismantling and block-

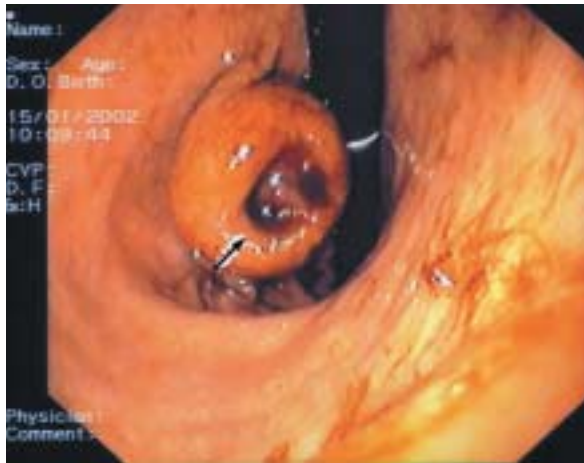

Figure 1. Endoscopic appearance of the giant gastric polyp at the passage from body to antrum. The clot on the top of the head is showed by the arrow.

ing with a clip. The snare was then kept in place passed throughout the nose like nasobiliary tube.

In the second step, performed one week later, endoscopic polypectomy was performed using a second polypectomy snare. Electrocautery current was supplied by the Söring 600 instrument (Söring Medizintechnik, Quickborn [Germany]), which was set on “blend” at 2. The polyp was transected immediately over the place of the first snare. The first polypectomy snare was kept in place (Figures 3 and 4) and the patient was discharged three hours after endoscopic polypectomy. We evaluated clinically the body temperature and the appearance of thoracic or/and abdominal pain

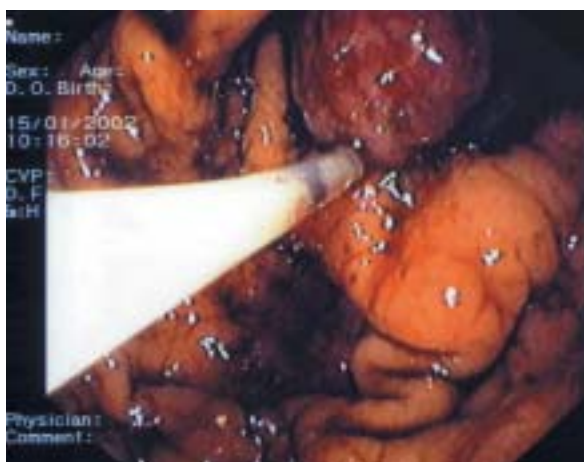

Figure 2. Placement of the first diathermic snare to prevent bleeding.

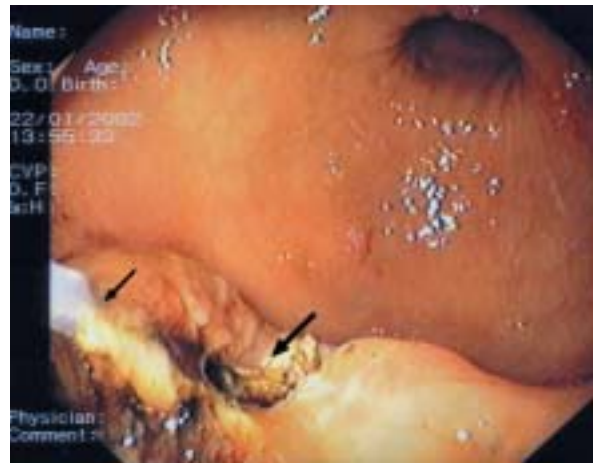

Figure 3. Endoscopic appearance of the stomach immediately after the endoscopic electro-surgical polypectomy (performed 7 days after placement of the first diathermic snare). Note the first snare (thin arrow) and presence of scarce blood, but no bleeding (thick arrow).

during the hospitalization, without occurrence of any complications. Finally, the first polypectomy snare sloughed off spontaneously and slipped out of the nose within 3 days after the endoscopic polypectomy. Histological evaluation of the transected polyp revealed neoplastic cells showing fusiform and epithelioid morphology according to a gastric submucosal leiomyoma (Figure 5 A, B).

Endoscopic control was performed one (Figure 6 A) and four (Figure 6 B) weeks later, showing complete reepithelization of the gastric mucosa. Histological evaluation

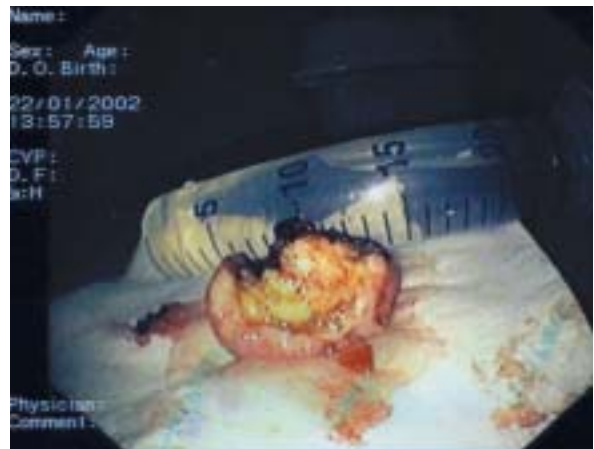

Figure 4. The giant gastric polyp on the table after extraction. Note the impressive size of the polyp compared with a syringe.

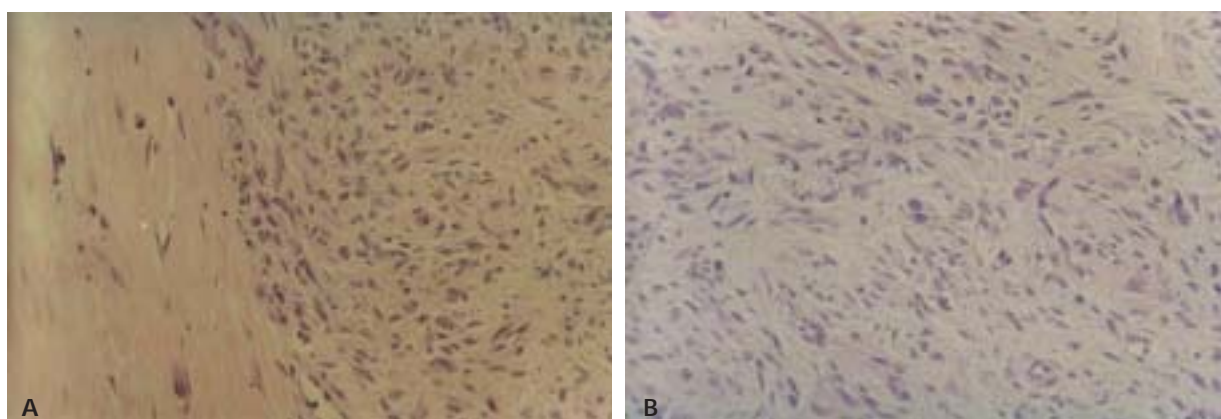


Figure 5. A, Histologic microphotograph showing neoplastic cell with fusiform and epithelioid morphology according to gastric leiomyoma. B, In this picture it is easy observable the well line of demarcation between neoplasia and muscular gastric wall of the stomach (ematoxylin & eosin, $\times 40$).

showed complete absence of muscular cells and presence of chronic gastritis. Endoscopic ultrasonography was also performed four weeks later without any endosonographic signs of recurrence of the disease. The last endoscopic examination was performed 12 months later, without any endoscopic or histological recurrence of the leiomyoma.

Discussion

Gastric leiomyoma is a rare benign tumour often asymptomatic. Only in the presence of

giant ones patients may experience symptoms such as compression, but rarely hemorrhage.

Surgery has been the treatment choice of leiomyoma for several years¹. However, less invasive methods, such as laparoscopic and/or endoscopic resection of leiomyoma, have been applied to leiomyomas of esophagus, stomach, duodenum and rectum^{1,2,6-10}.

In this case we used a new endoscopic technique to treat a bleeding leiomyoma mimicking a giant gastric polyp. We developed this technique to treat colorectal and gastric polyps larger than 2 centimeter^{4,5}. In the case reported, we modified our original technique of endoscopic polypectomy, treat-

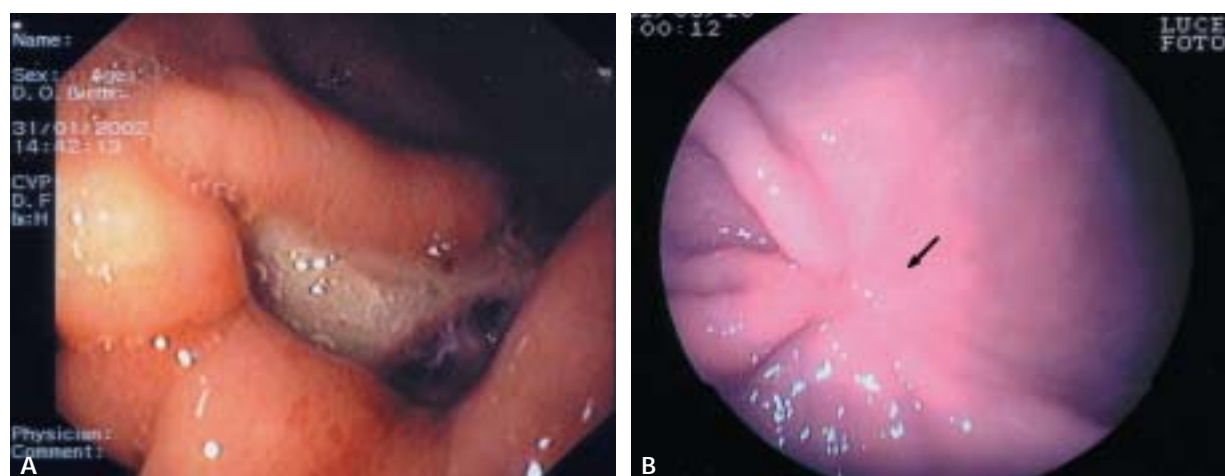


Figure 6. Endoscopic appearance of the site of polypectomy 1 (A) and 4 (B) weeks after endoscopic removal of the polyp. Note the absence of bleeding (A) and the complete re-epithelization of the mucosa (arrow).

ing the large gastric polyp (diameter of 4 centimeters) in two different endoscopic sessions. This two steps-approach permitted to us to obtain the optimal tightness (color of the polyp changed to dark red after ligation, and to pale pink at the time of the polypectomy seven days later) and to overcome the risk of bleeding after endoscopic polypectomy. In fact, the use of a standard diathermic snare permits an easier optimal tightness due to the presence of a manual mechanism of diathermic snare closure, by which a grading of the tightness is possible according to the thickness of the stalk.

The endoscopic polypectomy plays an important role in the management of gastrointestinal polyps. Unfortunately several complications may affect endoscopic polypectomy of gastric polyps, such as perforation, hemorrhage and symptomatic post-polypectomy ulcer¹¹. Several endoscopic methods have been developed to treat large gastric polyps (e.g., endoloop or hemoclip)^{11,12}, as well as a laparoscopic minimally invasive surgery, which is called "endo-organ gastric surgery"¹³. However, the use of endoloop is associated to bleeding developing as a result of transection of a thin stalk (4 mm), slippage of the loop in a semi-pedunculated lesion, or insufficient tightening of the loop¹⁴. Laparoscopic technique seems to be limited by greater costs than endoscopic polypectomy and by the presence of any condition that precludes safe PEG placement (such as obesity, ascites ect.)¹³. It has been proposed that a greater injection volume of saline solution would minimize these problems. However, this approach could reduce the immediate risk of bleeding in these cases but does not reduce the risk of delayed bleeding due to the size of the lesion. In conclusion, our new two-steps-technique could represent an optimal approach for the endoscopic removal of giant semi-pedunculated gastric polyps.

References

- 1) MATTHEWS BD, WALSH RM, KERCHER KW, et al. Laparoscopic vs open resection of gastric stromal tumors. *Surg Endosc* 2002; 16: 803-807.
- 2) SIU WT, LEONG HT, LI MK. Laparoscopic resection of bleeding gastric polyps. *Surg Endosc* 1997; 11: 283-284.
- 3) TRICARICO A, CIONE G, SOZIO M, et al. Digestive hemorrhages of obscure origin. *Surg Endosc* 2002; 16: 711-713.
- 4) BRANDIMARTE G, TURSI A. Endoscopic snare excision of large colorectal polyps: a new safe and effective technique. *Endoscopy* 2001; 33: 854-857.
- 5) TURSI A, BRANDIMARTE G. Endoscopic snare excision of large pedunculated gastric polyps: a new safe and effective technique. *Endoscopy* 2002; 34: 673-674.
- 6) KUME K, TAKASE I, HIROHATA Y, YOSHIKAWA I, ABE S, OTSUKI M. Endoscopic diagnosis in rectal leiomyoma. *Gastrointest Endosc* 2001; 53: 841.
- 7) BASSO N, ROSATO P, DE LEO A, et al. Laparoscopic treatment of gastric tumors. *Surg Endosc* 2000; 14: 524-526.
- 8) WOLFSOHN DM, SAVIDES TJ, EASTER DW, LYCHE KD. Laparoscopic-assisted endoscopic removal of a stromal-cell tumor of the stomach. *Endoscopy* 1997; 29: 679-682.
- 9) PAYNE WG, MURPHY CG, GROSSBARD LJ. Combined laparoscopic and endoscopic approach to resection of gastric leiomyoma. *J Laparoendosc Surg* 1995; 5: 119-122.
- 10) CHEN JB, KUDZU T, HISHIKAWA E, MIYAZAKI S. Endoscopic resection of large esophageal leiomyoma. *Endoscopy* 2002; 34: 428.
- 11) HACHISU T. A new detachable snare for hemostasis in the removal of large polyps or other elevated lesions. *Surg Endosc* 1991; 5: 70-74.
- 12) ABOU-ASSI SG, MIHAS AA, JOSEPH RM, SUBRAMONY C. Endoscopic hemoclip application for the treatment of a large gastric polyp causing intermittent outlet obstruction. *Gastrointest Endosc* 2003; 57: 433-435.
- 13) MITTAL SK, FILIPI CJ. Indications for endo-organ gastric excision. *Surg Endosc* 2000; 14: 318-325.
- 14) MATSUSHITA M, HAJIRO K, TAKAKUWA H, et al. Ineffective use of a detachable snare for colonoscopic polypectomy of large polyps. *Gastrointest Endosc* 1998; 47: 496-499.