European Review for Medical and Pharmacological Sciences 2024; 28: 90-97

Intramedullary locking mini-plate screw system in Lindgren osteotomy: a more effective fixation technique in mild and moderate hallux valgus cases

M. ULUÖZ, M.Y. GÖKMEN

Department of Orthopedics and Traumatology, University of Health Sciences, Adana City Training and Research Hospital, Adana, Turkey

Abstract. – OBJECTIVE: In the treatment of mild and moderate hallux valgus (HV) cases, the Lindgren distal osteotomy (LDO) technique has been one of the most frequently preferred methods, and screw fixation has been the most preferred material for surgery. However, considering the implant removal operations due to the reaction to the material, the risk of unsteadiness, retarded union, and malunion has limited the amount of safe application of lateralization of the distal fragment in distal osteotomy surgery and has yielded the researchers for a better alternative. This study compared the results of the LDO cases using headless cannulated screws and intramedullary plate fixation materials.

PATIENTS AND METHODS: The retrospective study included 31 files of patients operated for HV between January 1, 2018, and December 31, 2022, in Adana City Training and Research Hospital Orthopedics Clinic, Adana, Turkey. In the radiological evaluation, the hallux valgus angle (HVA), the intermetatarsal angle (IMA), the length of the first metatarsal (ML), and the distal metatarsal articular angle (DMAA) recorded preoperatively and postoperatively were analyzed. The functional results of the operations were evaluated by using the Visual Analog Scale (VAS), American Orthopedic Foot and Ankle Society (AOFAS), and EuroQol (EQ-5D) scores.

RESULTS: Postop HVA, IMA, MU, and DMMA values were significantly higher in patients in Group 1 than in patients in Group 2 ($p<0.001$; $p=0.004$; $p=0.004$; $p=0.049$; $p<0.001$, respectively). The change in Delta (Δ) HVA and EQ-5D values was significantly higher in patients in Group 2 compared to patients in Group 1 ($p=0.020$; $p=0.016$, respectively).

CONCLUSIONS: The easily available and low-cost locking plates produced for mini-fractures may safely be used in distal osteotomy surgery of mild and moderate HV successfully combined with screws if intramedullary-placed, allowing accurate lateralization and improving overall outcome.

Key Words:
Hallux valgus, Osteotomy, Distal metatarsal osteotomy, Mini-plate fixation, Headless screw fixation.

Introduction

Hallux valgus (HV) is a progressive foot deformity that occurs by the lateral deviation of the big toe and the medial deviation of the first metatarsal, causing the subluxation of the first metatarsophalangeal joint[1]. Epidemiological studies show that the disorder is mainly linked to hereditary factors, ligament laxity, non-conforming footwear, and other abnormalities, including pes planus, pronation of the hindfoot, and metatarsus primus varus. The deformity was classified into three groups - mild, moderate, and severe - by measuring the hallux valgus angle (HVA) and intermetatarsal angle (IMA) using weight-bearing radiographs[2]. Numerous treatment alternatives have been described for HV, including soft tissue procedures, arthrodesis, and osteotomies. The majority of the osteotomy techniques, although including minor differences in the implementation and various materials, aim to bring the HVA and IMA to normal limits by laterally displacing the fragment distal to the first metatarsal. In the treatment of mild and moderate cases, distal osteotomies, most commonly the Chevron and the Lindgren distal osteotomy (LDO) techniques, were the most frequently preferred methods, and screw fixation has been the most preferred material for surgery[3,4]. The LDO has been a relatively simpler transverse osteotomy of the first metatarsal by the lateral displacement of the distal fragment, often using a single oblique screw[5].

Nevertheless, considering the implant removal operations due to the reaction to the material, the

Corresponding Author: Mehmet Yiğit Gökmen, MD; e-mail: mehmet_yigit_gokmen@hotmail.com

risk of unsteadiness, retarded union, and malunion have limited the amount of safe application of lateralization of the distal fragment in distal osteotomy surgery and have yielded the researchers for a better alternative[6]. Recently, studies comparing the results of different materials used in distal osteotomies have emerged, indicating favorable outcomes[7,8]. This study compared the results of the LDO cases using headless cannulated screws and intramedullary plate fixation materials.

Patients and Methods

The retrospective study included 31 files of patients who had been operated for HV between January 1, 2018, and December 31, 2022, in Adana City Training and Research Hospital Orthopedics Clinic, Adana, Turkey. The data of the HV files of patients who underwent distal osteotomy as the primary intervention were investigated. The analyzed files included cases over the age of 18, mild and moderate HV, available weight-bearing radiographs pre-operatively, having been operated using the LDO technique, using headless cannulated screws or intramedullary plating, available weight-bearing radiographs and also at the sixth month post-operatively, and follow-up details for a minimum of twelve months following the surgery (Figure 1). The files of patients having a history of foot or ankle surgery, rheumatoid arthritis, degenerative osteoarthritis of the first metatarsophalangeal joint, chronic neurological or vascular diseases, diabetes mellitus, or having Body Mass Index (BMI) >30 kg/m^2 and incomplete data were not included in the analysis.

The patients were dichotomized into two groups based on the material used in the surgery. Group 1 included cases with headless cannulated screws and group 2 intramedullary plating.

Surgical Technique

Files of all cases included the same technique, beginning with a dorsomedial dermal incision of 4 cm on the first metatarsophalangeal joint. Following the dissection, the capsule was released and longitudinally incised. The metatarsal head and the bunion were uncovered. The part of the bunion involving the joint was removed. The LDO was performed as defined by Lindgren and Turan[5]. Osteotomy was performed diagonally at 30 degrees from the metatarsal long axis. The distal fragment was moved to the lateral and barely inferior. The distance of the displacement of the fragment piece was proportional to the required treatment. The fragments of group 1 were fixated by using titanium headless cannulated screws of 3 mm, and a titanium mini locking plate and screw system of 2 mm size were used in group 2 (Figure 2). The cortical screw fixated on the proximal fragment was tightened until the desired lateralization was achieved.

Following the fixation, in both groups, the sharp edging developed on the proximal portion due to the lateralization of the distal fragment was corrected by using microcutters, and capsular plication was then performed at the end (Figure 3).

Group 1 patients were operated on by the same surgeon, who had more than 15 years of experience in distal osteotomy. The operations in group 2 were performed by a different surgeon with a very similar level of experience.

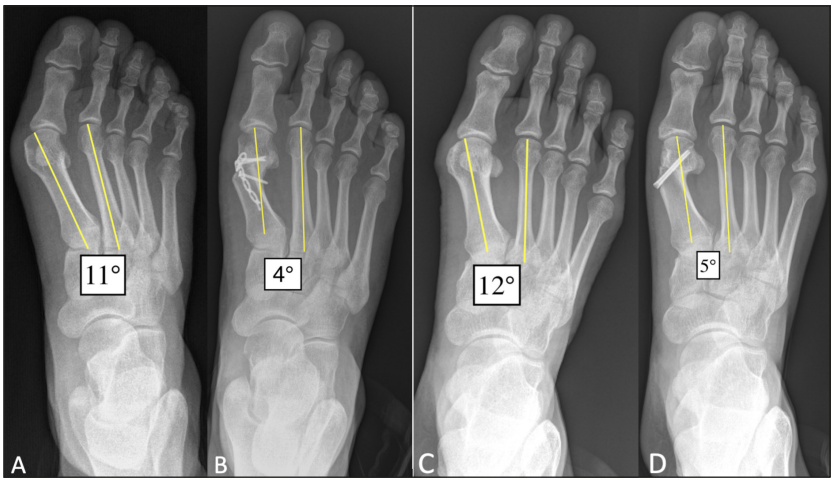

Figure 1. Intramedullary locking miniplate screw system, preoperative (**A**), and one year postoperative (**B**), Headless cannulated screw, preoperative (**C**), and one year postoperative (**D**) IMA measurement.

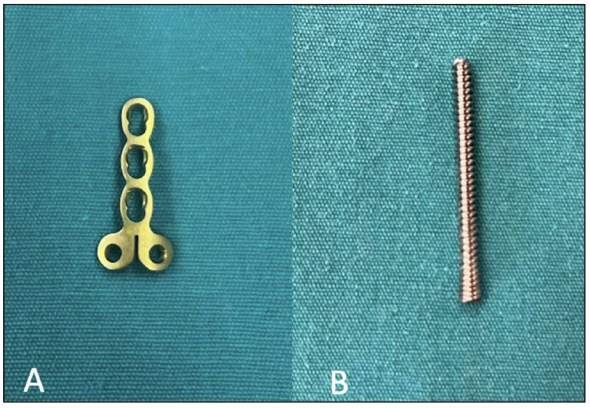

Figure 2. Fixation materials (**A**) titanium mini locking plate and screw system of 2 mm size, (**B**) titanium headless cannulated screw of 3 mm.

Figure 3. Intraoperative fluoroscopy image, removal of the stepping in the bone using a microcutter after placement of mini plate screw system.

Postoperative Care

None of the cases received splint fixation postoperatively. All cases were discharged the following day with HV shoes recommended for use for 45 days.

Radiological and Clinical Evaluation

The radiological measurements were conducted by a third surgeon other than the ones who had performed the operations. The radiological evaluation analyzed the HVA, the IMA, the first metatarsal length (ML), and the distal metatarsal articular angle (DMAA) were recorded preoperatively and postoperatively.

The functional results of the operations were evaluated by using the Visual Analog Scale (VAS), American Orthopaedic Foot and Ankle Society (AOFAS), and EuroQol (EQ-5D) scores.

The VAS scores were obtained from a horizontal 100-mm long scale, anchored by "no pain" (0) and "worst pain imaginable" (100). The averages of the total pain scores at rest and walking barefoot were noted[9].

The AOFAS, a modification of a forefoot score published previously for hallux valgus surgery and resection arthroplasty surgery, is a well-recognized clinical rating scale[10] for HV. A total score of 100 points is distributed by 40 points to pain, 45 to function, and 15 to alignment.

The EQ-5D is a usually widely used tool to assess mobility, self-care, usual activities, pain or discomfort, and anxiety or depression states. Each item is divided into three levels, resulting in a total between 5 and 15[11].

Statistical Analysis

SPSS (Statistical Package for the Social Sciences, IBM Corp., Armonk, NY, USA) 23.0 for Windows software was used for the statistical analysis of the data. Categorical measurements were summarized as numbers and percentages, and continuous measurements were summarized as mean and standard deviation (median and minimum-maximum where necessary). The asymmetrical distribution of the variable was analyzed using the Shapiro-Wilk test. The Chi-square test was used for comparisons of categorical expressions. Mann-Whitney U test was used for parameters that did not show normal distribution. The statistical significance level was set as 0.05 in all tests.

Results

Patients in Group 1 had higher preop HVA, IMA, and DMMA values (p=0.029; p<0.001; p<0.001, respectively) and lower VAS and AOFAS values than patients in Group 2 (p=0.040; p=0.045, respectively).

Postop HVA, IMA, ML, and DMMA values were significantly higher in patients in Group 1 than in patients in Group 2 (p<0.001; p=0.004; p=0.004; p=0.049; p<0.001, respectively).

The change in Delta (Δ) HVA and EQ-5D values was significantly higher in patients in Group 2 compared to patients in Group 1 (p=0.020; p=0.016, respectively).

No significant difference was found between the other parameters (p>0.05, Table I).

Table I. The overall analysis results of the groups.

	Group 1 (n=17)	Group 2 (n=14)	Total (n=31)	$p^{\dagger}$
	n (%)	**n (%)**	**n (%)**	
Gender				
Male	1 (5.9)	2 (14.3)	3 (9.7)	0.431
Female	16 (94.1)	12 (85.7)	28 (90.3)	
Side				
Right	5 (29.4)	6 (42.9)	11 (35.5)	0.436
Left	12 (70.6)	8 (57.1)	20 (64.5)	
	Mean±Std	**Mean±Std**	**Mean±Std**	$p^{\ddagger}$
Age (year)	35.94±13.57	38.86±8.30	37.26±11.41	0
Preoperative				
HVA	31.0±5.6	26.8±4.6	29.1±5.5	**0.029***
IMA	12.7±2.5	9.34±1.7	11.2±2.7	**<0.001****
ML	57.1±3.1	54.9±4.2	56.2±3.7	0.121
DMMA	28.2±6.0	20.3±3.9	24.6±6.5	**<0.001****
VAS	8.53±1.1	9.36±0.9	8.90±1.1	**0.040***
AOFAS	37.7±11.9	46.9±15.4	41.8±14.1	**0.045***
EQ-5D	11.1±.1	11.6±1.1	11.3±1.1	0.069
Postoperative				
HVA	15.36±6.6	5.83±5.4	11.05±7.7	**<0.001****
IMA	5.71±2.0	3.35±2.9	4.65±2.7	**0.004****
ML	55.59±3.3	53.10±4.5	54.46±4.0	**0.049***
DMMA	14.06±6.1	3.94±3.3	9.49±7.1	**<0.001****
VAS	1.35±1.1	1.07±0.9	1.23±1.1	0.590
AOFAS	90.3±5.5	91.7±5.7	90.9±5.5	0.413
EQ-5D	5.47±0.9	5.29±0.7	5.39±0.8	0.385
Delta (Δ)				
HVA	-15.7±6.5	-20.9±6.6	-18.0±6.9	**0.020***
IMA	-6.94±2.6	-5.98±3.1	-6.51±2.8	0.634
ML	-1.51±0.9	-1.89±0.9	-1.68±0.9	0.257
DMMA	-14.1±7.2	-16.3±4.5	-15.1±6.1	0.165
VAS	-7.17±1.7	-8.28±1.7	-7.67±1.8	0.057
AOFAS	52.6±12.5	44.9±15.0	49.1±14.0	0.070
EQ-5D	-5.64±1.2	-6.28±.8	-5.93±1.5	**0.016***
Follow-up (month)	18.47±2.5	18.71±3.5	18.58±2.9	0.888

$^{\dagger}p$-value was calculated using the Chi-square test, and $^{\ddagger}p$-value value was obtained using the Whitney U test. Significant at *$p<0.05$, and **$p<0.01$ level. Delta (Δ): Difference between postoperative – preoperative (change); HVA: Hallux valgus angle; IMA: Intermetatarsal angle; ML: First metatarsal length; DMMA: Distal metatarsal articular angle; VAS: Visual Analog Scale; AOFAS: American Orthopaedic Foot and Ankle Society; EQ-5D: EuroQol.

Discussion

The results of the demographics showed that there was no statistical significance between the groups in terms of age and gender. The female dominance observed in both groups was similar to the previous reports[12].

Other reports in literature show that Chevron and Lindgren's techniques are the most commonly preferred methods of distal osteotomy. Yet, the literature is abundant with conflicting reports, some indicating that neither was superior to the other and others reporting the advantages of one over the other for both techniques.

In this study, the significant difference in post-operative HVA in both groups should be highlighted. Studies[13] have shown that better lateralization of the distal fragment results in more successful sesamoid reduction and improved success. Esemenli et al[14] have reported that if the lateralization of the distal fragment may be performed by 7.2 mm, the sesamoid bone reduction might be achieved by 95% and suggested that in that case, the lateral sesamoid release would not be required.

The osteotomy methods using screws, as in group 1 patients, require the removal of the screw when adequate lateralization is not achieved. Redrilling the distal fragment may increase the risk of instability; thus, the surgeon distrusts the work. On the other hand, the locking plate and screw system, which was used in the patients in group 2, provides a dynamic and precise fixation

and avoids a potential screw removal procedure. The leveled accuracy of the procedure might explain the lower postoperative values in group 2.

The first metatarsophalangeal joint is a crucial factor in joint compatibility, and in cases with high DMAA, joint incompatibility may arise following the correction of IMA[15,16]. In addition to the lack of an apparent focus on the DMAA in the distal osteotomy techniques that use exclusively screws, particularly in patients in whom the majority of the distal fragment is lateralized, due to the screw fixation of the lateral fragment, DMAA might increase instead of a correction. However, as performed in group 2 patients, the plate is placed medially, and as the cortical screw pulls, the vector X force reduces the DMAA, and the vector Y force increases the lateralization of the distal fragment (Figure 4). In cases with normal DMAA values, the cortical screw angle to the cortex can be increased to reduce the vector X force. We think that the statistically significant lower DMAA values in group 2 are the results of the aforementioned feature of our technique.

In rare LDO cases, screw-related complications may occur, screws breaching the joint due to positioning the screw directing to the joint or a screw head too close to the dermis becoming palpable and generating discomfort (Figure 5). In the locking plate and screw system, the intramedullary placed plate is free from such potential discomforting problems.

Furthermore, in LDO, following lateralization of the distal fragment, the excision of the remaining medial stepping of the proximal fragment is limited in order to maintain a proper screwing site. In the latter method used in group 2, the implant is placed intramedullary; thus, the remaining stepped bone part may be removed totally (Figure 6).

Although there are reports[12] presenting the use of plates in LDO and highlighting the improved rehabilitation rates, the plates were static. They were placed dorsally under the extensor tendon, creating a risk of irritation.

Recently, intramedullary plates that enable locking at the proximal and distal ends have emerged for percutaneous osteotomy in HV cases[17-19]. The plates require special sets and lack an additional move to increase the lateralization following the screw fixation if the degree of the lateralization is not met. Percutaneous use may have advantages; nevertheless, Kauffman et al[20] have demonstrated no statistically significant difference between the open and closed distal osteotomies in a five-year follow-up period. On the other hand,

Figure 4. Intra-operative fluoroscopy image of the lateralization by tightening the cortical screw (demonstrating the vectorial forces).

Figure 5. Radiographic examinations of headless screw fixation-related complications in group 1 (**A**) screw head palpable under the skin, (**B**) the screw penetrating the first metatarsophalangeal joint.

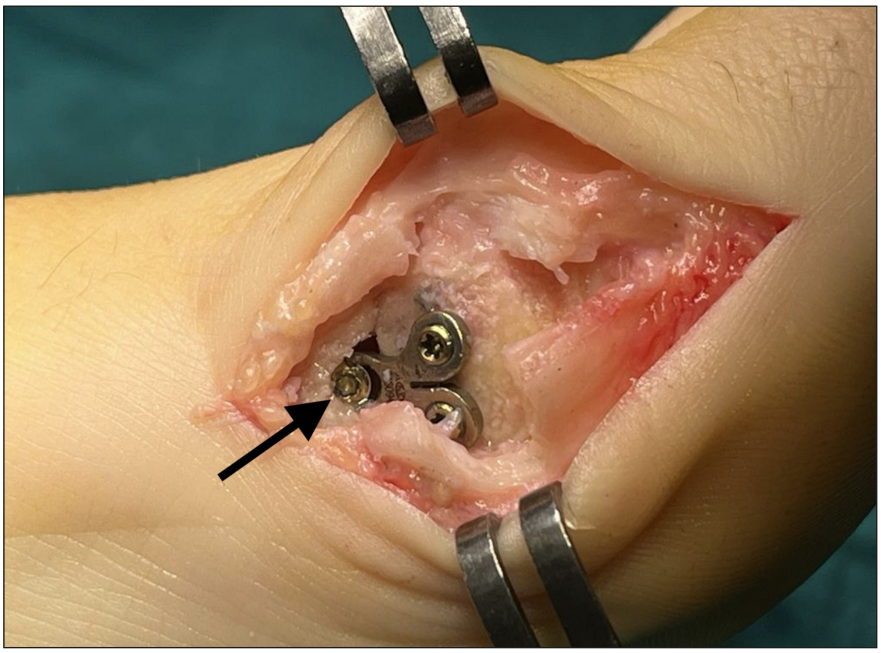

Figure 6. The placement of the cortical screw in the mini plate screw system (left foot) allows total removal of the stepping.

two other studies[6,18] shared promising outcome results using plates specifically designed for distal osteotomies. Still, in addition to the limited easy availability and the high cost, the immovable form of the locks placed at the distal fragment of the plates did not permit any correction maneuvers of the distal fragment after the fixation[6,18].

The statistically significant postoperative improvement of EQ-5D scores of group 2 was concordant with previous studies[13], suggesting that the correction of the HVA was proportionate to the overall improvement in patients. Moreover, the lack of a significant difference in the AOFAS and VAS scores supports the fact that the features of the surgery were very similar in both groups. Therefore, the postoperative scores did not differ statistically.

In our study, patients in group 2 underwent distal osteotomy using a locking plate and screw system, with plates manufactured for use in mini-fracture fixation and widely available, placed intra-medullary, which avoided the risk of irritation, allowed additional lateralization maneuvers after fixation (Figure 7), and was relatively inexpensive.

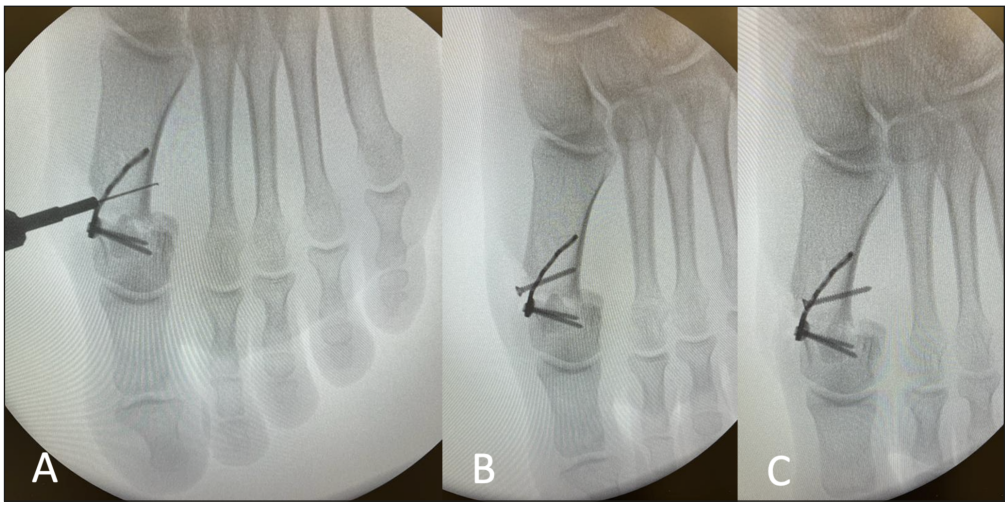

Figure 7. Intraoperative fluoroscopy images after the screw fixation of the distal fragment (**A**) length measurement before placement of the cortical screw, (**B**) Insertion of the cortical screw, (**C**), Increasing lateralization by tightening the cortical screw.

The literature search for a similar use of mini-plates placed intramedullary in distal osteotomy surgery for HV did not yield any results, which gives the idea that our study was the first to describe an intramedullary placed locking plate and screw combination may be used in distal osteotomy surgery of moderate HV successfully and reliably.

Limitations

The study's major limitations were the low number of cases, the short follow-up period, and the lack of comparison of the mini-plate with plates specifically designed for HV distal osteotomies. Nevertheless, we think that the value of the postoperative image data collected in the sixth month and an average follow-up duration of 18 months may be considered now acceptable. In the future, longer and more detailed follow-up studies are needed.

Conclusions

The easily available and low-cost locking plates produced for mini-fractures may safely be used in distal osteotomy surgery of mild and moderate HV successfully combined with screws if intramedullary-placed, allowing accurate lateralization and improving overall outcome.

Authors' Contributions

Both authors, M. Uluöz and M.Y. Gökmen, have contributed to the conceptualization, design, data collection, analysis, interpretation, manuscript preparation, and editing. Both authors have read and approved the final version of the manuscript.

Conflicts of Interest

The authors declare that there are no conflicts of interest.

Ethics Approval

The study was conducted according to the guidelines of the Declaration of Helsinki and approved by the Adana City Training and Research Hospital Clinical Research Ethics Committee (Meeting number: 134, Decision number: 2800).

Informed Consent

Due to the retrospective design of the study, informed consent was not applicable. The ethical board approved the data collection and the analysis of the patient files.

Funding

This study received no funding.

Data Availability

The data used in this study comprise the de-identified patient records saved in the ACH medical records archive, which regulations block open access. The permission for this research is limited to the researchers exclusively. Nevertheless, availability to third parties might be upon plausible request provided to the ACH Ethical Committee.

ORCID ID

Mesut Uluöz: 0000-0003-0319-3832
Mehmet Yiğit Gökmen: 0000-0003-1243-2057.

References

1) Mann RA, Coughlin MJ. Hallux valgus--etiology, anatomy, treatment and surgical considerations. Clin Orthop Relat Res 1981; 157: 31-41.
2) Hecht PJ, Lin TJ. Hallux Valgus. Med Clin North Am 2014; 98: 227-232.
3) Wagner E, Ortiz C. Osteotomy considerations in hallux valgus treatment: improving the correction power. Foot Ankle Clin 2012; 17: 481-498.
4) Zelen CM, Young NJ. Alternative Methods in Fixation for Capital Osteotomies in Hallux Valgus Surgery. Clin Podiatr Med Surg 2013; 30: 295-306.
5) Lindgren U, Turan I. A new operation for hallux valgus. Clin Orthop Relat Res 1983; 175: 179-183.
6) Palmanovich E, Myerson MS. Correction of Moderate and Severe Hallux Valgus Deformity with a Distal Metatarsal Osteotomy Using an Intramedullary Plate. Foot Ankle Clin 2014; 19: 191-201.
7) Acar B, Kose O, Turan A, Unal M, Kati YA, Guler F. Comparison of Bioabsorbable Magnesium versus Titanium Screw Fixation for Modified Distal Chevron Osteotomy in Hallux Valgus. Biomed Res Int 2018; 2018: 1-9.
8) Ray JJ, Friedmann AJ, Hanselman AE, Vaida J, Dayton PD, Hatch DJ, Smith B, Santrock, RD. Hallux Valgus. Foot Ankle Orthop 2019; 4: 247301141983850.
9) Collins SL, Moore RA, McQuay HJ. The visual analogue pain intensity scale: what is moderate pain in millimetres? Pain 1997; 72: 95-97.
10) Kitaoka HB, Alexander IJ, Adelaar RS, Nunley JA, Myerson MS, Sanders M. Clinical rating systems for the ankle-hindfoot, midfoot, hallux, and lesser toes. Foot Ankle Int 1994; 15: 349-353.
11) Rabin R, Charro FD. EQ-SD: a measure of health status from the EuroQol Group. Ann Med 2001; 33: 337-343.
12) Bayraktar TO, Yüce A, Yerli M, Tekin AC, Gürbüz H. Distal metatarsal osteotomy and dorsal neutralization plate in the treatment of hallux valgus. Eur J Orthop Surg Traumatol 2022; 32: 753-758.
13) Saro C, Andren B, Wildemyr Z, Felländer-Tsai L. Outcome after Distal Metatarsal Osteotomy for Hallux Valgus: A Prospective Randomized Controlled Trial of Two Methods. Foot Ankle Int 2007; 28: 778-787.

14) Esemenli T, Yildirim Y, Bezer M. Lateral Shifting of the First Metatarsal Head in Hallux Valgus Surgery: Effect on Sesamoid Reduction. Foot Ankle Int 2003; 24: 922-926.
15) Trnka HJ. Osteotomies for Hallux Valgus Correction. Foot Ankle Clin 2005; 10: 15-33.
16) Hardy RH, Clapham JCR. Observations on hallux valgus; based on a controlled series. J Bone Joint Surg Br 1951; 33-B: 376-391.
17) Gutteck N, Ulbricht M, Delank KS, Kielstein H, Schilde S. Minimally invasive hallux valgus correction with Internal Hallux Fixator® — A comparative cadaver study. Foot Ankle Surg 2022; 28: 378-383.
18) Matsumoto T, Gross CE, Parekh SG. Short-Term Radiographic Outcome After Distal Chevron Osteotomy for Hallux Valgus Using Intramedullary Plates With an Amended Algorithm for the Surgical Management of Hallux Valgus. Foot Ankle Spec 2019; 12: 25-33.
19) Díaz Fernández R. Use of a percutaneous osteotomy with plate fixation in hallux valgus correction. Foot Ankle Surg 2019; 25: 106-112.
20) Kaufmann G, Mörtlbauer L, Hofer-Picout P, Dammerer D, Ban M, Liebensteiner M. Five-Year Follow-up of Minimally Invasive Distal Metatarsal Chevron Osteotomy in Comparison with the Open Technique: A Randomized Controlled Trial. J Bone Joint Surg Am 2020; 102: 873-879.