

A new parameter in the diagnosis of vascular erectile dysfunction with penile Doppler ultrasound: cavernous artery ondulation index

D. YILDIRIM, I.H. BOZKURT*, B. GURSES**, A. CIRAKOGLU*

Department of Radiology and *Department of Urology, Kasimpasa Military Hospital, Istanbul, Turkey
**Department of Radiology, Yeditepe University Medical Center, Istanbul, Turkey

Abstract. – **AIM:** Our aim is to introduce the cavernous artery ondulation index (CA-OI) as a new parameter that could be accepted as an indirect indicator of vascular hemodynamics and also gives us information about the efficiency of erection.

PATIENTS AND METHODS: A total of 27 patients with erectile dysfunction were evaluated with penile Doppler ultrasonography (PDUS). After injection of papaverine intracavernously, arterial diameter and peak-systolic and end-diastolic velocities were measured. For measuring at a standart time, five minutes after injection, bilateral cavernosal arteries were examined and gray scale and color Doppler US images through the long axis were recorded at the mentioned phases. Cavernosal artery ondulation index (CA-OI) showing the amount of ondulation was calculated for each subject using these images.

RESULTS: In 9 of total 27 patients, erection could not pass the tumescence phase with 3 flaccid phases, while the remaining 18 had full erection. Mean CA-OI values were measured as 2.51 ± 0.37 mm, 3.15 ± 0.38 mm, and 2.68 ± 0.09 mm in normal, arterial insufficiency and venous insufficiency groups, respectively.

CONCLUSIONS: It is possible to differentiate the arterial insufficiency by using the cut-off value of CA-OI ≥ 2.5 values as a criteria.

Key Words:

Impotence, Arterial insufficiency, Venous insufficiency, Penile Doppler ultrasonography, Cavernosal artery ondulation index, CA-OI.

Introduction

Erectile dysfunction (ED) has been defined as persistent inability to attain and maintain an erection, sufficient to permit satisfactory sexual performance¹. Symptoms must be persistent for a minimum of 3 months to define it as an erectile dysfunction. Erectile dysfunction is an important health problem that effects the self-confidence,

social relationships and even work performance of the person. The first large scale, community-based study of ED was the Massachusetts Male Aging Study (MMAS)². In this study the prevalence of ED was reported as 2.6%. In another study the prevalence of ED was reported as 52% in non-institutionalized 40- to 70-year-old men in the Boston area in the USA³. If it is considered that only a small percent of the cases are admitting to the physician, because of social and psychological reasons, the real prevalence and importance of the disease would be better understood.

The diagnosis and treatment of erectile dysfunction has changed dramatically since the availability of safe and effective oral drugs. But some of the patients with ED could not be adequately treated with these medications, and might require more invasive tests for accurate diagnosis and treatment of the specific etiology. The main purpose of all these tests is to distinguish organic from neurological and/or psychological types of ED. Precise diagnosis of arterial insufficiency and venoocclusive failure is very important to permit an accurate and specific treatment. Color Doppler Ultrasonography is a valuable, informative and minimally invasive tool in the diagnosis of ED⁴. Although the diagnostic accuracy of arteriography, cavernosometry and cavernosography is greater, these tests are expensive, rather invasive, technically difficult and uncomfortable procedures with potential associated morbidities⁵⁻⁷. However, it is important to know the limitations and technical pitfalls of each study. Although the methodology of penile Doppler ultrasound is widely used and well accepted, a lack of agreement about validity of parameters that has been measured still exists. We aimed to evaluate the role of “cavernosal artery ondulation index-CA-OI” as a new distinguishing parameter for the diagnosis of arterial insufficiency.

Patients and Methods

In this prospective study, 27 patients who were referred from Urology Clinic for penile Doppler ultrasound (PDUS) because of erectile dysfunction were included. The mean age was 38 years (range 29-62 years). Institutional Review Board approval and informed consents of all the cases were obtained for this study, before injection. An intracavernous injection of papaverine (1 mg per age in years) was performed with 30 gauge thin needle in all subjects. All patients were evaluated with gray scale US and color Doppler ultrasound (CDUS) (GE Logic 9 Ultrasound Imager Milwaukee, WI, USA) just before injection and 1, 5, 15, 20 minutes after injection and the images were recorded. A 7.5 MHz linear transducer was used for the Doppler US examinations. The degree of erection was classified into flask erection, tumescence, full erection, rigid erection and detumescence phases by an urologist. Spectrum pattern, peak systolic velocity (PSV), end diastolic velocity (EDV) values and compliance were measured with conventional penile Doppler ultrasound 5 minutes after pharmacological stimu-

lation for each subject. Afterwards, right and left cavernosal arteries were visualized parallel to their longitudinal axis and the images were recorded. These images on the longitudinal axis were evaluated in an electronic medium and ondulation indexes for each case were calculated on digital images (Figure 1). Also compliance values were calculated for each artery from the views taken before and after (at the 3rd minute) pharmacologic stimulation at a standart point (the intersection point of 2/3 anterior and 1/3 posterior segment of the cavernous body). The compliance ratios and CA-OI values were shown in Table I.

Spectral peaks were obtained via a window placed with a 45-degree Doppler angle to the curve point of cavernosal arteries near radix penis at 1, 5, 15 and 20 minutes after injection and then PSV and EDV were calculated and recorded. Patients who had full or rigid erection, PSV ≥ 35 mm/sn, 0 mm/sn EDV (or retrograde end-diastolic flow), persistent erection more than 3 minutes, 60% or greater compliance ratios were evaluated as normal regarding the vascular hemodynamics. The subjects with insufficient erection

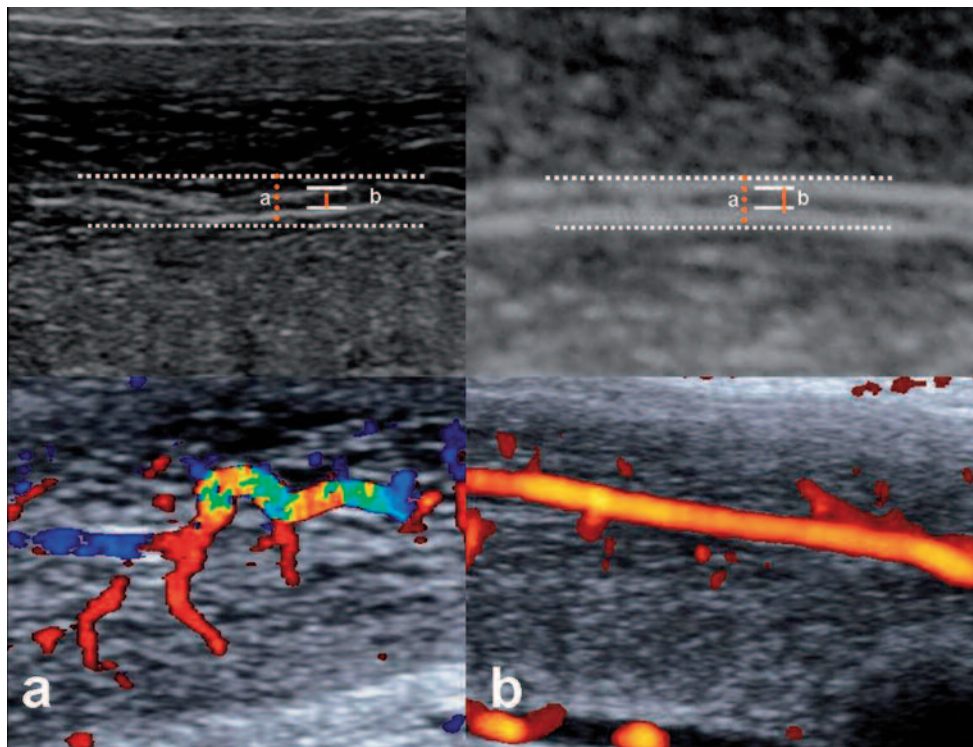


Figure 1. Color Doppler images of cavernous arteries in two different cases. Color Doppler image of an undulating (*a*) and power Doppler image of a flattened (*b*) trace of the related arteries. CA-OI = 3.1 of first case in a represents severe tortuosity, and CAOI = 2.2 for the other image shows less tortuous course of the examined cavernous arteries. And also it has been seen that the color aliasing in (*a*) which was related with the turbulence due to the zigzag flow. Whereas the flow in (*b*) shows laminary pattern.

which could not pass the tumescence phase, and cases with normal PSV but with high EDV (greater than 5 cm/sec) antegrade end diastolic flow accepted as to have veno-occlusive failure. Patients with insufficient erection which could not pass the tumescence and subjects with peak systolic velocities smaller than 25 cm/sec were accepted as having arterial insufficiency.

All measurements were performed by the same radiologist who experienced in penile Doppler imaging, using the same equipment, settings. Gray scale images, index measurements, index values and statistical evaluations were verified by another radiologist.

Statistical Analysis

Data was analyzed using SPSS for Windows version 15.0 (SPSS Inc., Chicago, IL, USA). The fitting to normal distribution of our population was shown with Kolmogorov Smirnov test ($p > 0.05$). The study groups were analyzed with ANOVA and Bonferroni tests (a kind of *post hoc* test). Mann-Whitney U test was added to statistical analysis because of low patient number and finally a $p < 0.05$ significance with 95% confi-

dent interval was achieved. Using the sensitivity and specificity values ROC curve was generated and area under curve measured.

Results

In 9 among 27 patients erection could not pass beyond the tumescence phase (in 3 subjects the penis was flaccid), while the remaining 18 had either full (n=11) or rigid (n=7) erection. Three of 9 patients that had deficient erection were evaluated as venous insufficiency with a ≥ 6 cm/sec antegrade persistence of end diastolic flow. The other 6 patients with $PSV \leq 25$ cm/sec were evaluated as arterial insufficiency.

Spectral examination was in normal limits in other subjects who did not have erectile disorder. In all these 18 subjects the PSV values were > 35 cm/sec, and except for one patient whose EDV was measured zero, the rest had EDV values changing between -3 and -9 cm/sec in retrograde direction. The radiological diagnosis of all the subjects was also in harmony with and confirmed by urological examination and clinical evaluation.

Table I. For all of the subjects, calibration of tortuosity (a value), artery calibration (b value), cavernous artery ondulation index (CA-OI value) and compliance values are given in detail.

Number	A	b	CA-OI (a/b)	Compliance (%)	Patient
1	2.2	1.0	2.2	71	Normal
2	2.6	1.3	2	68	Normal
3	3.2	1.4	2.28	71	Normal
4	2.6	1.1	2.36	80	Normal
5	2.8	1.1	2.54	77	Normal
6	3.1	1.2	2.58	66	Normal
7	2.7	1.3	2.07	61	Normal
8	2.9	1.2	2.41	76	Normal
9	2.8	1.1	2.54	72	Normal
10	2.2	1.1	2.0	65	Normal
11	3.2	1.3	2.46	63	Normal
12	3.1	1.2	2.58	68	Normal
13	2.6	0.9	2.84	61	Normal
14	2.1	0.8	2.62	62	Normal
15	2.7	1.1	2.45	78	Normal
16	3.6	1.4	2.57	70	Normal
17	3.2	0.9	3.55	66	Normal
18	3.6	1.2	3.0	61	Normal
19	3.1	1.1	2.82	49	Arterial insufficiency
20	3.3	1.0	3.0	51	Arterial insufficiency
21	3.7	1.2	3.08	53	Arterial insufficiency
22	3.9	1.0	3.90	42	Arterial insufficiency
23	2.7	0.9	3.0	49	Arterial insufficiency
24	3.4	1.1	3.09	47	Arterial insufficiency
25	2.8	1.3	2.65	61	Venous incompetence
26	2.6	1.0	2.6	63	Venous incompetence
27	3.3	1.2	2.78	59	Venous incompetence

The confirmation of our quantitative measurements was also performed with the aid of statistical data, provided by compliance index measurements, besides clinical urologic evaluation. The CA-OI and compliance value of each subject is shown in Table II. typical spectrum patterns, color and gray scale longitudinal axis images of each three groups were presented as in Figure 2. Regarding both the CA-OI values and compliances, the statistical differences among two groups (normal and arterial insufficiency) were significant ($p = 0.003$; $p = 0.0000002$; respectively). On the other hand, the difference for those parameters is not statistically significant between normal and venous insufficiency group ($p > 0.05$).

As far as compliance values are concerned, there is statistically significant difference between the arterial insufficiency, normal and venous insufficiency groups (p values are 0.00000001; 0.01; 0.02, respectively). Area under curve was 0.963 for compliance, whereas was measured as 0.889 for CA-OI. Both of the AUC measurements were in perfect ($p < 0.05$) for the normal group and patients with arterial insufficiency.

Discussion

Erectile dysfunction (ED, “male impotence”) is a sexual dysfunction characterized by the inability to develop or maintain an erection of the penis sufficient for satisfactory sexual performance. Dysfunction may occur as a result of psychogenic, organic (hormonal, neurologic, pharmacologic, vascular problems) or of mixed (organic plus psychogenic) disorders. Recent researches indicate that vascular disease secondary to arterial, venous, or mixed vascular insufficiency is the underlying etiology in a large number of patients with impotence⁸. The prevalence rate of ED was 2.6% in a large scale

study although very different reported results exist². The prevalence of ED is reported to increase with age, low education level, diabetes mellitus, hypertension, benign prostatic hyperplasia, and with smoking⁸. It now appears that an organic basis could be recognized in more than 50% of impotent patients, and “vasculogenic impotence” is the most frequent organic cause². As nonprosthetic therapy options become available, the accurate diagnosis of vasogenic impotence has gained great importance which allows appropriate surgical intervention.

Erection begins with an autonomic neurogenic impulse that induces relaxation of the cavernosal arterioles and sinusoidal spaces. This results in an increase in arterial flow into the corpora cavernosa, producing sinusoidal expansion and elongation. Compression of the efferent veins against the tunica albuginea limits venous return. Ultimately, complete venous occlusion produces tumescence^{9,10}.

To accurately assess patients with erectile dysfunction, it is necessary to demonstrate the progression of hemodynamic events leading to erection. Specific diagnostic criteria have been reported for the assessment of the causes of the erectile dysfunction. Chiou et al¹¹ determined this progression by simultaneously monitoring intracavernosal pressure and cavernosal artery spectral waveforms in normal volunteers and they have observed the different phases. The sonographic evaluation of erectile dysfunction was pioneered by Lue et al¹²: many Authors have used duplex sonography for the determination of cavernosal artery flow velocities to accurately characterize arterial integrity. In the past several years, considerable attention has been focused on the Doppler evaluation of erectile dysfunction. In most of the previous studies, it has been emphasized that evaluation of the penile vascular hemodynamics throughout the Doppler US examination offers more accurate results, than the technique which includes injection of papaverine and examination

Table II. The number of patients of the three separate groups according to the diagnosis, the average values measured in conjunction with standard deviations and related confidence intervals.

		n	Mean	Standard deviation	95% confidence interval for mean	
					Lower bound	Upper bound
CA-OI (a/b)	Normal	18	2.50	0.37	2.32	2.69
	Arterial insufficiency	6	3.15	0.38	2.75	3.55
	Venous incompetence	3	2.68	0.09	2.45	2.91
Compliance (%)	Normal	18	68.67	6.15	65.61	71.73
	Arterial insufficiency	6	48.50	3.78	44.53	52.47
	Venous incompetence	3	61.00	2.00	56.03	65.97

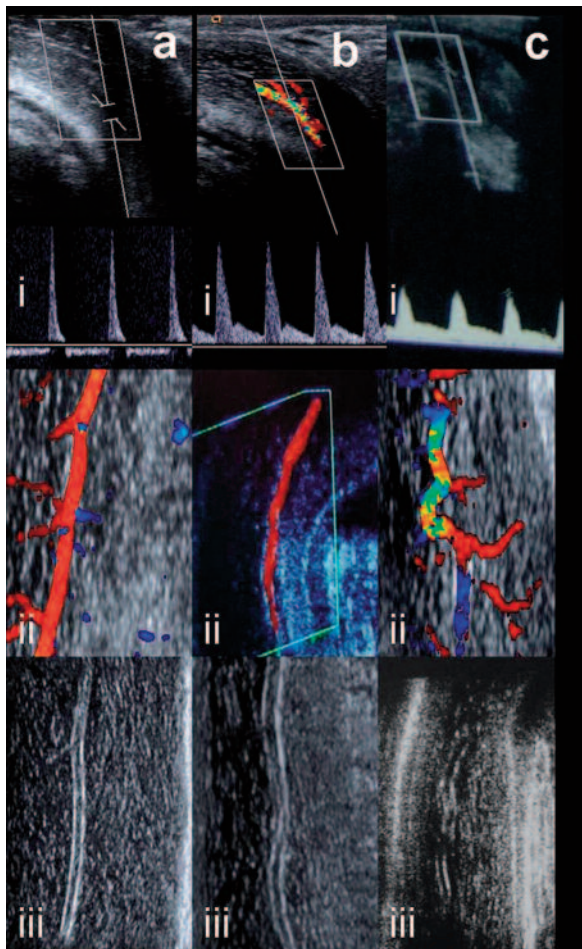


Figure 2. Images from different subjects. (a) Normal, (b) with venous insufficiency, (c) with arterial insufficiency. In these three separate groups: spectral patterns (i), color Doppler images (ii) and gray scale images obtained parallel to the longitudinal axis of the related cavernous arteries are shown.

only after erection has occurred¹³. Because Doppler US is capable of accurately characterizing the nature of flow within the cavernous arteries, dorsal veins, it is widely used for imaging the penile flow hemodynamics. Doppler US is the least invasive method to evaluate the penile vascular hemodynamics. Caversonometry, caversonography, electromyography (EMG) of cavernous bodies and selective pudental arteriography are the advanced and rather invasive diagnostic tests that should be reserved for suspicious cases which can not be definitely diagnosed by Doppler US (e.g. subjects with PSV between 25-35 cm/sec, some complicated patients which have venous insufficiency or having complex vascular pathologies)^{11,12}. These methods are not used commonly in routine practice because of their invasive nature, which are also more expensive and time consuming techniques.

There are many parameters that have been used to evaluate the vascular status of men with erectile dysfunction up to now, which are mainly: PSV, EDV, acceleration time, cavernosal artery acceleration index, vascular resistance, compliance of cavernous artery and cavernous artery intima-media thickness. Although the combination of some of these criteria was used in some studies, actually, PSV, EDV and cavernous artery compliance values are the current widespread used and clinically accepted parameters^{11,12,14}.

After pharmacological stimulation, PSV values < 25 cm/sec were accepted as arterial insufficiency, and PSV values > 35 cm/sec were accepted as normal cavernous artery flow. On the other hand, PSV values ranging between 25 cm/sec and 35 cm/sec have been accepted as suspicious for arterial insufficiency. For those subjects, additional parameters (clinical findings such as degree and persistence of erection or neuro-psychiatric disorders) must be evaluated accordingly, for final diagnosis^{15,16,17}. In a number of previously published studies, although the EDV values between 3 and 7 cm/sec has been accepted as normal, the main concern which present totally normal veno-occlusive mechanism is zero diastolic flow or retrograde venous flow patterns on spectral window. According to those data, veno-occlusive mechanism and arterial insufficiency could be assessed with PSV, EDV and the spectral pattern on pulsed wave Doppler US examination^{14,15}. However, it is noteworthy to mention that the veno-occlusive mechanism may not work properly in some patients with arterial insufficiency, due to deficient inflow to increase the intracavernous pressure for closure of the emissary connections. These patients should not be evaluated as veno-occlusive mechanism failure^{11,14-17}. Right at this point, we believe that the parameter used in our study could be an alternative way to evaluate the possible vascular pathology for those cases with equivocal findings. In this study, we have used CA-OI as a Doppler US parameter in the diagnosis of erectile dysfunction for such suspicious cases. We found out that patients with arterial insufficiency and normal subjects could be distinguished by this new parameter. In our study, considering only the CA-OI indexes, we were able to diagnose patients having arterial insufficiency with 100% sensitivity, and 78% specificity. The accuracy of these values were also confirmed with compliance rates and spectral examination findings. As a result, secondary venous insufficiency could

be clearly differentiated from primary veno-occlusive mechanism defects by the presence of abnormal CA-OI values.

In the previous reports which have been focused on measuring parameters like PSV, acceleration and resistivity index during Doppler US examination, it was concluded that the arterial insufficiency could be diagnosed with a 35%-100% sensitivity and 46%-89% specificity in patients with erectile dysfunction^{4,5}. The values obtained from our study are highly sensitive (100%), similar to the studies that have applied multiple parameters. In addition to this, CA-OI parameter has an acceptable (78%) specificity when compared with the literature data, even when considered as a single parameter^{11,16}.

Our study has several limits. First of all, the most important limitation was arising from Doppler US technique itself. This technique is an operator dependent method and it is affected to an important degree from shift angles. We tried to overcome this problem using a standard angle and PRF values in Doppler US examinations which were performed by a single radiologist. Another problem was the verification of the diagnosis, because of the invasiveness and difficulty of other further (gold standard) procedures. In this situation we tried to make the final diagnosis with combination of Doppler US findings, clinical examination and the response to the treatment.

In the literature, many studies regarding systemic arteries have demonstrated a correlation between tortuosity and atherosclerosis^{18,19}. Although controversial data, no matter it is a result of the process, it is often seen along with the atherosclerotic mural changes through the related arteries^{20,21}. The long axis of vessel that becomes harder after atherosclerosis, has tendency to undulate more with systolic blood pressure^{19,22}. These alterations are most remarkably seen in abdominal aorta and iliac artery segments. And it is also reasonable to put forward the same theory for cavernous arteries. Some tortuosity may be discovered in the course of the cavernous arteries when influenced by atherosclerosis^{19,22}. We believe that we achieved near standard conditions and we performed the examinations with new technology high resolution superficial transducers to delineate the cavernous artery courses.

So with applying the condition on the cavernous arteries, we found out that the tortuosity of them directly has been affected by degree or type of impotence. It is important to know that tortuosity may be described as a visual sign in

great arteries. But it has to be formulated when using in smaller arteries to relieve of a risk of operator dependency. So, we aimed to quantify the increased tortuosity and tried to calculate it as CA-OI value. We found that the CA-OI was increasing concordant with the degree of atherosclerosis.

Conclusions

Tortuosity may be used in the discrimination of abnormalities of arterial origin during evaluation of impotent cases. In our study, when the cut-off is taken as 2.5 mm for OI, with only that parameter, patients with arterial insufficiency could be distinguished with %100 sensitivity and 78% specificity. Although it is not included in our case groups, we are also thinking that it shall be useful in cases with PSV: 25-30 cm/sec, whose are evaluated as having suspicious arterial insufficiency. Our findings have to be tested in larger studies. Also the implementation of new software programs which can calculate the CA-OI automatically will contribute the test for becoming a practical and widespread method.

Conflict of Interest

None to declare.

References

- 1) SHAFIK A, SHAFIK I, EL SIBAI O, SHAFIK AA. On the pathogenesis of penile venous leakage: role of the tunica albuginea. *BMC Urol* 2007 5; 7: 14.
- 2) JOHANNES CB, ARAUJO AB, FELDMAN HA, DERBY CA, KLEINMAN KP, MCKINLAY JB. Incidence of erectile dysfunction in men 40 to 69 years old: Longitudinal results from the Massachusetts male aging study. *J Urol* 2000; 163: 460-463.
- 3) ARAUJO AB, TRAVISON TG, GANZ P, CHIU GR, KUPELIAN V, ROSEN RC, HALL SA, MCKINLAY JB. Erectile dysfunction and mortality. *J Sex Med* 2009; 6: 2445-2454.
- 4) GOLUBUNSKI AJ, SIKORSKI A. Usefulness of power Doppler ultrasonography in evaluating erectile dysfunction. *BJU Int* 2002; 89: 779-782.
- 5) MELMAN A, CHRIST GJ. The hemodynamics of erection and the pharmacotherapies of erectile dysfunction. *Heart Dis* 2002; 4: 252-264.
- 6) BENSON CB, ARUNY JE, VICKERS MA JR. Correlation of duplex sonography with arteriography in patients with erectile dysfunction. *AJR Am J Roentgenol* 1993; 160: 71-73.

- 7) ROSEN M, GREENFIELD A, WALKER TG, GRANT P, GUBEN JK, DUBROW J, BETTMANN MA, GOLDSTEIN I. Arteriogenic impotence: findings in 195 impotent men examined with selective internal pudendat angiography. *Radiology* 1990; 174: 1043-1048.
- 8) MELMAN A, GINGELL JC. The epidemiology and pathophysiology of erectile dysfunction. *J Urol* 1999; 161: 5-11.
- 9) GILLON G, BARNEA O. Erection mechanism of the penis: a model based analysis. *Urol* 2002; 168: 2711-2715.
- 10) BOROWITZ E, BARNEA O. Hemodynamic mechanisms of penile erection. *IEEE Trans Biomed Eng* 2000; 47: 319-326.
- 11) CHIOU RK, POMEROY BD, CHEN WS, ANDERSON JC, WOBIG RK, TAYLOR RJ. Hemodynamic patterns of pharmacologically induced erection: evaluation by color Doppler sonography. *J Urol* 1998; 159: 109-112.
- 12) LUE TF, HRICAK HH, MARICH KW, TANAGHO EA. Vasculogenic impotence evaluated by high resolution ultrasonography and pulsed Doppler spectrum analysis. *Radiology* 1985; 155: 777-781.
- 13) AVERSA A, ISIDORI AM, CAPRIO M, CERILLI M, FRAJESE V, FABBRI A. Penile pharmacotesting in diagnosing male erectile dysfunction: evidence for lack of accuracy and specificity. *Int J Androl* 2002; 25: 6-10.
- 14) TEH HS, LIN MB, TSOU IY, KHOO TK, LIM PH, NG FC, CHIN CM, PEH SO, HO SH, NG KK, FONG YK. Penile colour duplex ultrasonography as a screening tool for venogenic erectile dysfunction. *Ann Acad Med Singapore* 2002; 31: 165-169.
- 15) KIM SC. Recent advancement in diagnosis of vasculogenic impotence. *Asian J Androl* 1999; 1: 37-43.
- 16) COPEL L, KATZ R, BLACHAR A, SOSNA J, SHEIMAN RG. Clinical and duplex US assessment of effects of sildenafil on cavernosal arteries of the penis: comparison with intracavernosal injection of vasoactive agents—initial experience. *Radiology* 2005; 237: 986-991.
- 17) VALJI K, BOOKSTEIN JJ. Diagnosis of arteriogenic impotence: efficacy of duplex sonography as a screening tool. *AJR Am J Roentgenol* 1993; 160: 65-69.
- 18) SMEDBY O, BERGSTRAND L. Tortuosity and atherosclerosis in the femoral artery: what is cause and what is effect? *Ann Biomed Eng* 1996; 24: 474-480.
- 19) DEL CORSO L, MORUZZO D, CONTE B, AGELLI M, ROMANELLI AM, PASTINE F, PROTTI M, PENTIMONE F, BAGGIANI G. Tortuosity, kinking, and coiling of the carotid artery: expression of atherosclerosis or aging? *Angiology* 1998; 49: 361-371.
- 20) DOUGHERTY G, VARRO J. A quantitative index for the measurement of the tortuosity of blood vessels. *Med Eng Phys* 2000; 22: 567-574.
- 21) STEHBENS WE. Mechanisms underlying arterial fragility and the complications of atherosclerosis. *Pathobiology* 1997; 65: 1-13.
- 22) FITZGERALD SW, ERICKSON SJ, FOLEY WD, LIPCHIK EO, LAWSON TL. Color Doppler sonography in the evaluation of erectile dysfunction: patterns of temporal response to papaverine. *AJR Am J Roentgenol* 1991; 157: 331-336.