

# Complete transmural gastric migration of PTFE mesh after surgery for a recurrent hiatal hernia

V. PORZIELLA<sup>1</sup>, A. CESARIO<sup>1,4</sup>, F. LOCOCO<sup>1</sup>, S. MARGARITORA<sup>2</sup>, G. LEUZZI<sup>1</sup>, M. MARCHESE<sup>3</sup>, L. PETRUZZIELLO<sup>3</sup>, G. COSTAMAGNA<sup>3</sup>, P. GRANONE<sup>1</sup>

<sup>1</sup>Department of Thoracic Surgery, Catholic University of Sacred Heart, Rome, Italy

<sup>2</sup>Department of Thoracic Surgery, Centro Oncologico Fiorentino, Florence, Italy

<sup>3</sup>Digestive Endoscopy Unit, Catholic University of the Sacred Heart, Rome, Italy

<sup>4</sup>Deputy Scientific Director, IRCCS San Raffaele Pisana, Rome, Italy

**Abstract.** – Complications directly associated with the use of prosthetic materials in large hiatal hernia repair are rarely cited events in the literature. We herein report a case of a 47 year-old woman who came to our attention for a subacute onset of severe dysphagia and weight loss. She previously underwent laparoscopic Nissen fundoplication with PTFE dual-mesh cruroplasty for a large recurrent hiatal hernia. With the clinical suspicion of “Tight Nissen”, an endoscopy was performed and revealed a circular stenosis in the lower esophagus, a rotation of the stomach and, surprisingly, the presence of PTFE mesh free-moving in the gastric lumen. With the use of rattooth forceps, the foreign body was removed and, after few days, the patient underwent a surgical debridement of hiatal scar tissue and a gastropexy procedure.

In conclusion, dysphagia may manifest during the early postoperative period after mesh repair antireflux surgery, but such dysphagia usually resolves; if it doesn't or if it worsens, mesh migration must be excluded.

*Key Words:*

Transmural gastric migration, PTFE, Hiatal hernia.

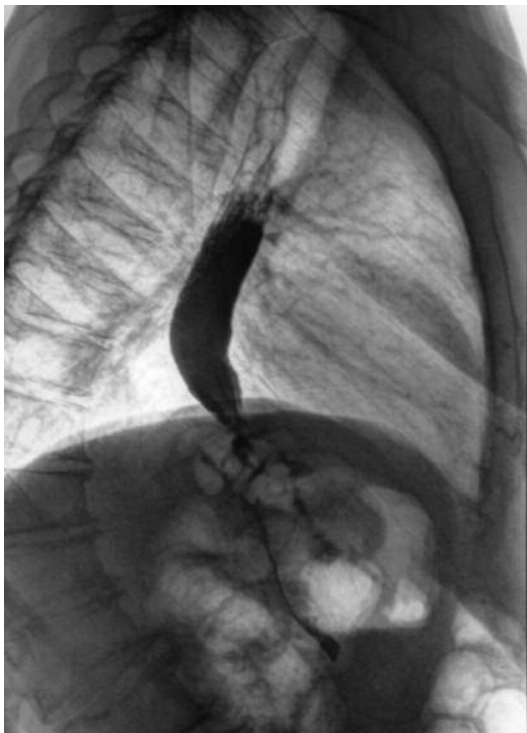## Case Presentation

A 47-year-old woman came to our attention for a subacute onset of severe dysphagia and weight loss. She previously underwent laparoscopic Nissen fundoplication with cruroplasty for a large recurrent hiatal hernia. During last surgical procedure, a “dog-shaped” expanded polytetrafluoroethylene (PTFE) dual mesh was placed. With the clinical suspicion of “Tight Nissen”, a barium swallow examination was performed and the anomalous esophago-gastric transit was confirmed (Figure 1). Endoscopy revealed a circular stenosis in the lower esophagus, a rotation of the

stomach (with the greater curvature completely revolved in anterior position) and, surprisingly, the presence of PTFE-Mesh, identified as a whitish shrunken material, free-moving in the gastric lumen (Figure 2). No mucosal lesions were seen. With the use of rat-tooth forceps, the foreign body was removed (Figure 3) without any complications (see video-clip). After few days, only a partial improvement was obtained. Thus, the patient underwent a surgical debridement of hiatal scar tissue and a gastropexy procedure (greater curvature fixed to the abdominal wall). 6 months after surgery, the patient is almost symptomless as remarked by barium swallow examination (Figure 4).

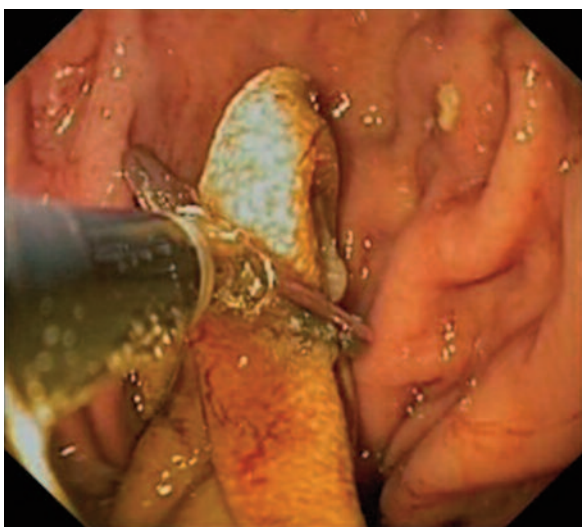## Discussion

One of the most frequently occurring structural failures of the Nissen fundoplication is migration or “slipping” of the wrap into the chest. Thus, in the last decade, there has been increasing interest in the use of mesh reinforcement of the hiatal repair. Polytetrafluoroethylene (PTFE) is one of the materials that have been used for this purpose, as it is thought to induce minimal tissue reaction. Even if relatively safe, complications directly associated with the use of prosthetic materials in large hiatal hernia repair are rarely cited events in the literature<sup>1</sup>. In particular, although none of the randomised controlled trials of mesh-reinforced hiatal closure in adults have reported postoperative mesh erosion either into the oesophagus or fundus, there are some case reports in the literature; two from polypropylene mesh repair, one from Teflon repair, one from dacron repair and four from PTFE repair<sup>2-3</sup>. Also in these studies, the patients have frequently reported severe dysphagia as an initial problem, as

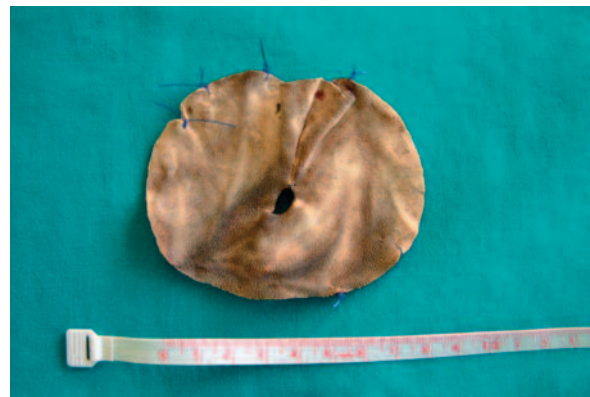

**Figure 1.** Barium swallow examination: anomalous esophago-gastric transit and hiatal stenosis.

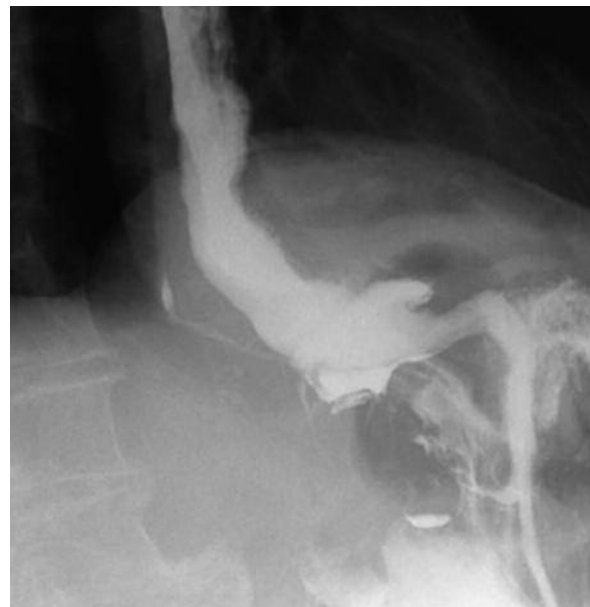
in the present case. In conclusion, dysphagia may manifest during the early postoperative period after mesh repair antireflux surgery, but such dysphagia usually resolves; if it doesn't or if it worsens, mesh migration must be excluded.



**Figure 2.** Endoscopic finding of the foreign body: the PTFE Mesh appears as a whitish shrunken material free-moving in the gastric lumen.



**Figure 3.** The PTFE Mesh after the removal.



**Figure 4.** Barium swallow examination (performed 6 months after surgery) showing normalized esophago-gastric transit.

## References

- 1) TATUM RP, SHALHUB S, OELSCHLAGER BK, PELLEGRINI CA. Complications of PTFE Mesh at the diaphragmatic hiatus. *J Gastrointest Surg* 2008; 12: 953-957.
- 2) HERGUETA-DELGADO P, MARIN-MORENO M, MORALES-CONDE S, REINA-SERRANO S, JURADO-CASTILLO C, PELICER-BAUTISTA F, HERRERIAS- GUTIERREZ JM. Transmural migration of a prosthetic mesh after surgery of a paraesophageal hiatal hernia. *Gastrointest Endosc* 2006; 64: 120.
- 3) CARPELAN-HOLMSTRO M, KRUUNA O, SALO J, KYLA"NPAA" L, SCHEININ T. Late mesh migration through the stomach wall after laparoscopic re-fundoplication using a dual-sided PTFE/ePTFE mesh. *Hernia* 2011; 15: 217-220.