

# A new and reliable landmark in parotid surgery: tragomastoid groove (Akil Groove)

F. AKIL, V. KINIS, U. YILMAZ, M. AKDAG, S.F. TOPRAK, M. AYRAL, H. DURAK

Department of Otorhinolaryngology and Head and Neck Surgery, School of Medicine, Dicle University, Diyarbakır, Turkey

**Abstract. – OBJECTIVE:** Parotid surgery is a frequently performed surgery in otorhinolaryngology practice with many possible complications. Due to the high ratio of facial paralysis during parotid surgery, we defined a new landmark for identifying and protecting the facial nerve as early as possible during surgery.

**MATERIALS AND METHODS:** The study was designed as a prospective anatomical method. The important details and relationship of the tragomastoid groove to the facial nerve truncus were examined during surgery on 30 patients. In addition, the demographics of the patients, the type of surgery and the pathological results of surgeries were evaluated.

**RESULTS:** The mean distance of the tragomastoid groove to the facial nerve truncus was  $20.53 \pm 1.71$  mm, the mean deepness of the tragomastoid groove was  $1.91 \pm 0.26$  mm, and the mean superficial part of the tragomastoid groove was  $0.83 \pm 0.23$  mm. The tragomastoid groove was situated either across from the facial nerve at the place where the facial nerve truncus exits the stylomastoid foramen or just inferior to the truncus in all patients.

**CONCLUSIONS:** The tragomastoid groove was defined for the first time in the literature as a reliable landmark for identifying the facial nerve truncus easily during parotid surgery.

## Key Words:

Tragomastoid groove, Facial nerve truncus, Landmark, Facial nerve paralysis, Parotid surgery.

## Introduction

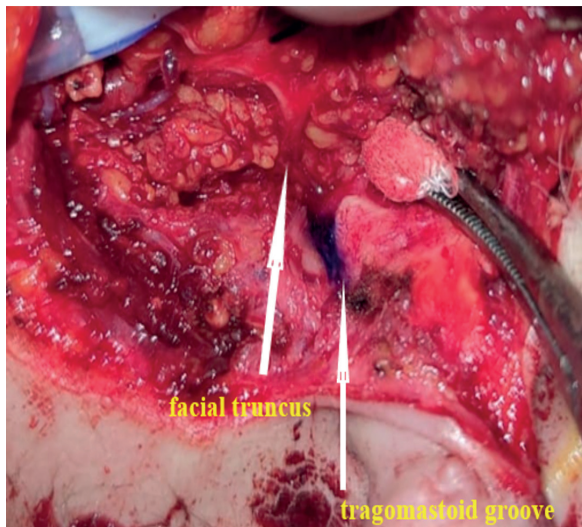
Parotid surgery is a frequently performed operation in otorhinolaryngology practice. While it is performed mostly for benign masses in the parotid gland, it is also performed for the treatment of malignant and rarely seen pathologies. Whether for benign or malignant tumors, facial nerve paralysis is still an important problem during parotid surgery.

Although the facial nerve can be found by antero-grade or retrograde approaches, the anterograde way is still the most often used method. Unfortunately, the incidence rates of temporary and permanent facial nerve paralysis are 34.4% and 2.4%, respectively, in parotid surgery<sup>1</sup>. Temporary or permanent facial nerve paralysis risk increases in case of the inability to find the facial nerve truncus (FNT) and its branches. In addition to a clean and wide-open surgical area, some landmarks are very helpful in the determination of the facial nerve. The tragal pointer, posterior belly of the digastric muscle and transmastoid suture are the most often used and reliable landmarks during parotid surgery. Despite the increasing use of these landmarks and the use of facial nerve monitorization, the definition of FNT can be still an important problem during parotid surgery. This problem extends the surgery time and increases the risk of facial nerve paralysis. In this study, we tried to define the relationship of a new landmark, called the “tragomastoid groove (TMG) (Akil groove)”, with the facial nerve. This groove can be easily and reliably used as a landmark for the identification of the FNT.

## Materials and Methods

### Study Design

The study was begun after approval from the Ethics Committee. It was planned as a prospective study. Intraoperative measurements of 30 patients who were operated for parotid pathologies between 2019 and 2020 at the University Department of Otorhinolaryngology were recorded. We tried to define a new landmark that can be useful in the demonstration of the FNT during parotid surgery. We called this landmark the TMG (Akil groove). The groove which extends from stylomastoid foramen until the exit facial nerve is called the TMG.



**Figure 1.** The anatomic relationship of TMG with FNT.

The groove is situated between the inferior border of the tragal cartilage and the mastoid apex (Figures 1 and 2). We made 3 measurements for this groove: the most superficial part, the deepest part of this groove and the length of TMG. In addition to the measurements, the position of the FNT in this groove was noted. The demographics of patients, the pathologic results of surgeries and the types of surgeries were recorded.

### ***Surgical Technique***

A modified Blair incision in the supine position under general anesthesia was performed in all patients. In the preauricular region, the skin flap was elevated between the superficial musculoaponeurotic layer and the parotid capsule. The flap was elevated until the anterior border of the gland. The sternocleidomastoid muscle was our posterior border. Then, the parotid gland was separated from other tissues by dissection of the gland. The posterior belly of the digastric muscle was determined. Then, the auricularis magnus nerve, which crosses over the sternocleidomastoid muscle, was identified. The posterior branch of this nerve was protected as much as possible. The auricula was retracted posteriorly with a suture. In the superior region, dissection was performed deeply between the tragal cartilage and the posterior border of the parotid gland. The tragal pointer and the inferior border of the tragal cartilage were detected. The mastoid apex, which is the upper border of the sternocleidomastoid muscle and attaches to the mastoid bone, was seen. At this level, the TMG

(Akil groove), which is formed between the mastoid apex and the inferior border of the tragal cartilage, was detected (Figures 1 and 2). Then, the measurements of this groove and the relationship between the TMG and the FNT were determined. After the identification of the FNT and protection of its branches, either a partial or a total parotidectomy was performed.

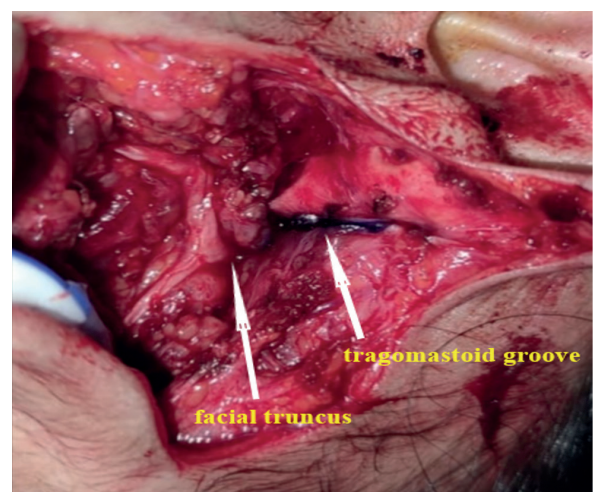
### ***Ethics Approval***

This study was approved by the Ethics Committee of the University Faculty of Medicine with decision number 19, dated 05.12.2019.

## **Results**

### ***General Results***

Fourteen male and 16 female patients were included in the study. One of the male patients was a 1-year-old baby. The mean age of the male group was 38 years, and the mean age of the female group was 41 years. The mean age of all patients was 39.6 years. The preoperative fine needle aspiration biopsy results were as follows: 20 benign lesions, 4 malignancies suspicious, 3 malignancies, 3 atypical cells, and 1 lipoma. The postoperative histopathological results were as follows: 13 pleomorphic adenomas, 6 Whartin tumors, 1 lipoma, 1 lipoblastoma, 1 mucoepidermoid carcinoma, 1 acinic cell carcinoma, 3 squamous cell carcinomas, 1 ductal adenocarcinoma, 1 lymphoma and 1 basal cell carcinoma (Table I).



**Figure 2.** The borders of TMG.

**Table I.** Demographic data of patients, pathological results and type of surgeries.

Patient	Age	Gender	Fnab	Patology	Surgery
1	60	Man	Bening	Whartin tumor	Partial arotidectomy
2	54	Man	Benign	Lipoma	Partial parotidectomy
3	39	Man	Bening	Plemorphic adenoma	Partial parotidectomy
4	32	Woman	Bening	Plemorphic adenoma	Partial parotidectomy
5	29	Woman	Bening	Plemorphic adenoma	Partial parotidectomy
6	27	Woman	Suspected omalignancy	Low grade mucoepidermoid carcinoma	Total parotidectomy
7	1	Man	Atypical adipose tissue	Lipoblastoma	Partial parotidectomy
8	29	Woman	Bening	Plemorphic adenoma	Partial parotidectomy
9	45	Woman	Malignancy	Squamous cell carcinoma	total parotidectomy
10	56	Woman	Bening	Bazal cell carcinoma	Partial parotidectomy
11	61	Woman	Suspected malignancy	Acinic cell carcinoma	Total parotidectomy
12	59	Man	Suspected malignancy	Lymphoma	Total parotidectomy
13	74	Woman	Malignancy	Squamous cell carcinoma	Total parotidectomy
14	73	Man	Suspected malignancy	Squamous cell carcinoma	Total parotidectomy
15	78	Man	Bening	Whartin	Partial parotidectomy
16	46	Man	Bening	Plemorphic	Partial parotidectomy
17	74	Man	Bening	Whartin tumor	Partial parotidectomy
18	23	Woman	Bening	Plemorphic adenoma	Partial parotidectomy
19	31	Woman	Bening	Plemorphic adenoma	Partial parotidectomy
20	35	Woman	Bening	Plemorphic adenoma	Partial parotidectomy
21	53	Man	Bening	Whartin tumor	Partial parotidectomy
22	58	Woman	Malignancy	Low grade mucoepidermoid ca	Partial parotidectomy
23	62	Woman	Atypical cell	High grade ductal adenocarcinoma	Total parotidectomy
24	46	Woman	Bening	Pleomorphic adenoma	Partial parotidectomy
25	45	Woman	Bening	Pleomorphic adenoma	Partial parotidectomy
26	50	Woman	Bening	Pleomorphic adenoma	Partial parotidectomy
27	55	Man	Bening	Warthin tumor	Partial parotidectomy
28	32	Man	Bening	Pleomorphic adenoma	Partial parotidectomy
29	49	Man	Bening	Pleomorphic adenoma	Partial parotidectomy
30	51	Man	Bening	Warthin tumor	Partial parotidectomy

Fnab: Fine Needle Aspiration Biopsy.

### Results of Tragomastoid Groove (Akil Groove) Measurements

The distances from the beginning of the TMG to the facial FNT were  $20.71 \text{ mm} \pm 0.57$  in men and  $20.37 \pm 0.37 \text{ mm}$  in women. This distance was 15 mm in the 1-year-old male baby. The mean distance was calculated as  $20.53 \pm 1.71 \text{ mm}$  in 30 patients. The mean deepest parts of this groove were  $1.85 \pm 0.08 \text{ mm}$  in men and  $1.95 \pm 0.05$  in women. The mean most superficial parts of the TMG were  $0.82 \pm 0.06 \text{ mm}$  in men and  $0.84 \pm 0.05 \text{ mm}$  in women. In the total of 30 patients, the mean measurements were  $1.91 \pm 0.26 \text{ mm}$  for the deepest part and  $0.83 \pm 0.23 \text{ mm}$  for the most superficial part. When we examined the vertical axis, the FNT crossed the middle part of the TGM in 22 patients and was located inferior to this groove in 8 patients. The FNT was not found at the superior part of the TGM in any patients in our study. Therefore, the

TGM can be used as an easy, quick and reliable landmark to find the FNT (Table II).

### Discussion

Parotid surgery still has a high facial nerve paralysis risk. It is accepted that the risk of temporary facial paralysis is between 10-50% and 0.5% for permanent facial paralysis<sup>2,3</sup>. While the injuries associated with the facial nerve are still at these rates, the main purpose of parotid surgery is to remove the tumor safely without nerve injury<sup>4</sup>. Many landmarks have been identified for this purpose, and most of them help the surgeons in finding the FNT without nerve injury. In our study, we tried to focus on this topic. We discussed a new landmark, which we call the TMG (Akil groove).

**Table II.** The measurements of Tragomastoid Groove.

Patient	Distance (mm)	Depth (mm)	Superficial part (mm)	The position FNT to TMG
1	24	2	1	Middle
2	20	2	1	Middle
3	23	2	1	Just inferior
4	22	1,5	0,5	Middle
5	21	2	1	Middle
6	19	1,5	0,5	Just inferior
7	15	1	0,5	Middle
8	20	2	1	Middle
9	4	2	0,5	Middle
10	19	2	1	Middle
11	20	2	1	Middle
12	21	2	1	Just inferior
13	20	2	1	Just inferior
14	19	2	1	Middle
15	20	1,5	0,5	Middle
16	23	2	1	Middle
17	20	2	1	Just inferior
18	21	2	0,5	Middle
19	22	2	1	Just inferior
20	20	2	1	Middle
21	21	2	1	Middle
22	22	2	1	Middle
23	21	2	1	Middle
24	22	2,5	1	Just inferior
25	18	2	0,5	Middle
26	19	2	1	Just inferior
27	21	1,5	0,5	Middle
28	22	2	1	Middle
29	20	2	0,5	Middle
30	21	2	0,5	Middle

FNT: Facial Nerve Truncus; TMG: Tragomastoid Groove

The results showed that the distance between the TMG to the FNT changed minimally from patient to patient (Table II). In addition to this finding, we found that the groove rises above the truncus in each case (Figures 1 and 2). The easy demonstration of the TMG intraoperatively and the high directivity of this groove to the facial nerve truncus make this groove an important landmark. Ecartation of the auricula in the posterosuperior direction and the wide opening of the surgical field make this groove more prominent. Thus, the surgeon can identify this groove more easily and quickly during parotid surgery.

When we look at other landmarks in the literature, the tragal pointer was defined by Conley et al<sup>5</sup>, and it was stated that the deepest part of the tragal cartilage is helpful in finding the FNT; in other words, the relationship of the facial nerve with the anteroinferomedial tip of

the tragal cartilage (tragal pointer) was demonstrated. Currently, the tragal pointer is the most commonly used landmark to demonstrate FNT<sup>6</sup>, and the mean distance between the tragal pointer to the FNT is 13.6±11.0 mm. However, as the tragal cartilage is mobile, the position of the cartilage can be changed during retraction of the auricula, which is an important disadvantage of this landmark. In our study, we found that although the inferior border of the tragal cartilage forms the superior border of the TMG, the mobile tragal cartilage does not disturb the groove anatomy, and retraction of the auricula makes this groove more prominent. The tympanomastoid suture is a more fixed landmark to identify the facial nerve. In many studies, tympanomastoid suture is accepted as one of the best landmarks due to its fixed position and close relationship with the stylomandibular fo-



ramen<sup>7,8</sup>. However, the use of this suture as a landmark has some disadvantages: it requires periosteal elevation, and the dense sternocleidomastoid muscle tendon structure adhering to the mastoid tip covers the tympanomastoid suture<sup>9-11</sup>.

The posterior belly of the digastric muscle is again an important landmark. However, it is a more variable landmark than the tympanomastoid suture. The distance between posterior belly of digastric muscle to the FNT is very variable between 4-12 mm<sup>6,12</sup>.

The styloid process is also a parameter defined for the first time by Lapthrop and used as a landmark due to its association with the FNT<sup>13</sup>. Although its close anatomy to the facial nerve seems to be an important advantage, the deeper localization and its variable length are the disadvantages of this landmark<sup>7,14</sup>.

In addition to the classic landmarks, new landmarks have been defined for safer and easier surgeries. The posterior auricular artery is one of them. In a study conducted in 2018 performed on 10 cadavers, it is stated that the posterior auricular artery is crossed with the facial nerve at the inferior part of the stylomandibular foramen. FNT can be found easily by following the posterior auricular artery which is very close to nerve<sup>15</sup>. However, bleeding and deterioration of the surgical orientation may cause facial nerve paralysis during the identification of the posterior auricular artery due to close relationship. In a study published in 2019 and conducted on 8 cadavers, the relationship of the FNT and the parotid-mastoid fascia was examined. It was stated that especially as the parotid fascia travels over the FNT it can be used as a landmark<sup>16</sup>. Borle et al<sup>17</sup> described the relationship of a triangle and the FNT at a live surgery in 2019. At a study performed in 2015, by combining radiological findings with prospective clinical and cadaveric studies, it was stated that the facial nerve can be found easily and safely at the place between the posterior belly of the digastric muscle and the styloid process<sup>18</sup>. Meybodi et al<sup>19</sup>, in a study in 2019, noted that by finding the digastric branch of the facial nerve, the FNT can be easily found. Upile et al<sup>20</sup> defined the stylomastoid artery and its relationship with the FNT; it is located lateral to the facial nerve. When we compare our study with other studies in the literature the stable anatomy of the groove despite the interventions during surgery, the clear anatomic relationship with the facial nerve and its sufficiency for being a lone landmark in finding the FNT are its advantages.

## Conclusions

Demonstration of the FNT is one of the most difficult stages for surgeons dealing with parotid surgery. We think that the TMG is a very reliable landmark that can facilitate the discovery of the FNT. Contrary to many landmarks defined in the literature, it is thought that it can be used alone easily, which will make the TMG a very frequently used landmark in parotid surgery.

---

## Availability of Data

The datasets analyzed during this study were obtained from patients files and hospital computer system, therefore are not available publicly. But they are available from the corresponding author on reasonable request.

---

## Ethical Approval

This study was approved by the Ethics Committee of the University Faculty of Medicine with decision number 19, dated 05.12.2019. .

---

## Conflict of Interest

The Authors declare that they have no conflict of interests.

---

## Consent for Participation

Informed consent was obtained from children and parents who volunteered to participate in the study..

---

## Funding

This research did not receive any specific grant from funding agencies in the public, commercial, or not-for-profit sectors.

---

## Orcid Numbers

Ferit Akil: 0000-0001-5479-9311.  
Vefa Kinis: 0000-0002-4528-5594.  
Umit Yilmaz: 0000-0003-1227-153X.  
Mehmet Akdag: 0000-0003-1377-4227.  
Hayrullah Durak: 0000-0003-0300-6638.  
Serdar Ferit Toprak: 0000-0003-3879-8794.  
Muhammed Ayral: 0000-0002-2421-4842.

## References

- 1) Stankovic P, Wittlinger J, Timmesfeld N, Stephan SH, Georgiew R, Günzel T, Teymoortash A, Wilhelm T.
- 2) O'Brien CJ. Current management of benign parotid tumors-the role of limited superficial parotidectomy. *Head Neck* 2003; 25: 946-952.

- 3) Leverstein H, van der Wal JE, Tiwari RM, van der Waal I, Snow GB. Surgical management of 246 previously untreated pleomorphic adenomas of the parotid gland. *Br J Surg* 1997; 84: 399-403.
- 4) Greyling LM, Glanvill R, Boon JM, Schabert D, Meiring JH, Pretorius JP, van Schoor A. Bony landmarks as an aid for intraoperative facial nerve identification. *Clin Anat* 2007; 20: 739-744.
- 5) Conley JJ, Glands S. Facial nerve. New York, NY: Grune & Stratton; 1975.
- 6) Ji YD, Donoff RB, Peacock ZS, Carlson ER. Surgical Landmarks to Locating the Main Trunk of the Facial Nerve in Parotid Surgery: A Systematic Review. *J Oral Maxillofac Surg* 2018; 76: 438-443.
- 7) Tabb HG, Scalco AN, Fraser SF. Exposure of the facial nerve in parotid surgery. (Use of the tympanomastoid fissure as a guide). *Laryngoscope* 1970; 80: 559-567.
- 8) Gray H. Anatomy of the Human Body. Philadelphia: PA Lea & Febiger; 1918.
- 9) Pather N, Osman M. Landmarks of the facial nerve: implications for parotidectomy. *Surg Radiol Anat* 2006; 28: 170-175.
- 10) Nishida M, Matsuura HA. Landmark for facial nerve identification during parotid surgery. *J Oral Maxillofac Surg* 1993; 51: 451-443.
- 11) Browne HJ. Exposure of the facial nerve. *Br J Surg* 1988; 75: 724-725.
- 12) Saha S, Pal S, Sengupta M, Chowdhury K, Saha, VP and Mondal L. Identification of facial nerve during parotidectomy: a combined anatomical & surgical study. *Indian J Otolaryngol and Head and Neck Surg* 2014; 66: 63-88.
- 13) Lathrop FD. Technic of exposing the facial nerve as an aid to surgery of the parotid gland. *Surg Clin North Am* 1949; 29: 673-677.
- 14) Beahrs OH. The surgical anatomy and technique of parotidectomy. *Surg Clin North Am* 1977; 57: 477-93.
- 15) Liu M, Wang SJ, Benet A, Meybodi AT, Tabani H, El-Sayed IH. Posterior auricular artery as a novel anatomic landmark for identification of the facial nerve: a cadaveric study. *Head Neck* 2018; 40: 1461-465.
- 16) Micucci SB, Cheng SS, Song T, Rasgon B. The Role of the Parotid-Mastoid Fascia in Identification of the Facial Nerve Trunk During Parotidectomy. *Ear Nose Throat J*. 2019 Oct 3;145561319877998. doi: 10.1177/0145561319877998. Epub ahead of print.
- 17) Borle RM, Jadhav A, Bhola N, Hingnikar P, Gaiikwad P. Borle's triangle: a reliable anatomical landmark for ease of identification of facial nerve trunk during parotidectomy. *J Oral Biol Craniofac Res* 2019; 9: 33-36.
- 18) Joseph ST, Sharankumar S, Sandya CJ, Sivakumar V, Sherry P, Krishnakumar T, Subramania I. Easy and Safe Method for Facial Nerve Identification in Parotid Surgery. *J Neurol Surg B Skull Base* 2015; 76: 426-431.
- 19) Meybodi AT, Moreira LB, Lawton MT, Preul, MC. Anatomical assessment of the digastric branch of the facial nerve as a landmark to localize the extratemporal facial nerve trunk. *Surg Radiol Anat* 2019; 41: 657-662.
- 20) Upile T, Jerjes W, Nouraei SA, Singh SU, Kafas P, Sandison A, Sudhoff H, Hopper C. The stylomastoid artery as an anatomical landmark to the facial nerve during parotid surgery: a clinico-anatomic study. *World J Surg Oncol* 2009; 7: 71.