European Review for Medical and Pharmacological Sciences 2023; 27: 5841-5853

Therapeutic effects of cinnamon bark oil on sciatic nerve injury in rats

O. OZHAN[1], S.F. IZCI[2], M. HUZ[3], M. COLAK[1], Z. KUCUKAKCALI[4], H. PARLAKPINAR[1]

[1]Department of Pharmacology, Faculty of Medicine, İnönü University, Malatya, Turkey
[2]Faculty of Pharmacy, İnönü University, Malatya, Turkey
[3]Department of Pathology, Faculty of Medicine, İnönü University, Malatya, Turkey
[4]Department of Biostatistics and Medical Informatics, Faculty of Medicine, İnönü University, Malatya, Turkey

Abstract. – OBJECTIVE: The aim of this study was to investigate the effects of cinnamon bark essential oil (CBO) on analgesia, motor activity, balance, and coordination in rats with sciatic nerve damage.

MATERIALS AND METHODS: Rats were divided into three groups as simply randomized. The right sciatic nerve (RSN) of the Sham group was explored. Only vehicle solution was applied for 28 days. The RSN of the sciatic nerve injury (SNI) group was explored. Damage was created by unilateral clamping, and vehicle solution was applied for 28 days. The RSN of the sciatic nerve injury+cinnamon bark essential oil (SNI+CBO) group was explored. SNI was created by unilateral clamping and CBO was applied for 28 days. In the experiment study, motor activity, balance, and coordination measurements were made with rotarod and accelerod tests. A hot plate test was performed for analgesia measurements. Histopathology studies were carried out with the sciatic nerve tissues.

RESULTS: In the rotarod test, there was a statistically significant difference between the SNI group and the SNI+CBO group ($p<0.05$). According to the accelerod test findings, there was a statistically significant difference between the SNI group with the Sham and SNI+CBO groups. In the hot plate test, there was a statistically significant difference between the SNI group with the Sham and SNI+CBO groups ($p<0.05$). In comparison to the Sham group and the SNI group, the SNI+CBO group was shown to have the greatest expression level of vimentin.

CONCLUSIONS: We have concluded that CBO can be used as an adjuvant treatment in cases of SNI, increased pain, nociception, impaired balance, motor activity, and coordination. Our results will be supported by further studies.

Key Words:
Sciatic nerve injury, Cinnamon bark oil, Motor activity, Analgesia, Vimentin.

Introduction

The peripheral nervous system (PNS) is an active system that surrounds our body and informs the central nervous system (CNS) of every situation that occurs by providing transmission between the senses. The etiology of damage in this system can be caused by conditions such as gunshot wounds, stab wounds, and traffic accidents. When nerve damage occurs, loss of function may occur, ranging from mild paresthesia to complete loss of sensation or mild weakness to total paralysis. The severity of the developing lesion is determined by factors such as the amount of pressure, its duration, and the area where it is applied. Although these damages do not endanger the person's life, they put the person under a tremendous social and economic burden[1,2].

Peripheral nerve injuries are classified under three headings by Seddon (1942)[3]. These are neuropraxia, axonotmesis, and neurotmesis. Wallerian damage is also important in all three titles. However, the most prevalent cause of sciatic nerve lesions is hip trauma, which includes intramuscular injections, penetrating trauma, contusion, hip fracture surgery, and nerve compression. Gunshot wounds, lacerations, femoral shaft fractures, contusions, penetrating trauma, and iatrogenic injuries are among the most common causes of thigh injuries[4,5]. In sciatic nerve lesions, there is weakness in the hamstring muscles and all muscles below the knee and loss of sensation in the tibial and peroneal nerve distribution[5].

Cinnamon essential oil is derived from the *Cinnamon zeylanicum* Blume plant. The most important active substances in cinnamon composition are cinnamaldehyde and eugenol at a rate of 60-70%, benzaldehyde at a rate of 5-10%, tannins, and essential oil at a rate of 1-2%[6].

Corresponding Author: Onural Ozhan, Ph.D; e-mail: onural.ozhan@inonu.edu.tr

Cinnamon oil contains *trans*-cinnamaldehyde, which has anti-inflammatory and antioxidant effects[7]. In addition, cinnamon bark oil (CBO) can have an anti-inflammatory effect by inhibiting cyclooxygenase activity and prostaglandin formation[8]. Singh et al[9] reported the antioxidant activity of essential oils prepared from cinnamon bark and leaves in their study in 2007. In the study by Chericoni et al[10] in 2005, CBO and the eugenol compound isolated from it were proven to have a strong antioxidant effect.

Today, many studies[11-13] are carried out on the treatment of peripheral nerve injury. The study aims to present the effectiveness of CBO in analgesia, motor activity balance, and coordination in sciatic nerve damage. To that end, CBO, with a proven antioxidant and anti-inflammatory effect, which is thought to affect the oxidative stress and inflammatory process in the physiopathology of this damage, was administered to rats *via* orogastric gavage in order to alleviate damage to the sciatic nerve.

Materials and Methods

Cinnamon Bark Oil

CBO contains less than 3% cineole, 1-6% linalol, 1-4% β-caryophyllene, less than 0.5% safrole, 55-75% trans-cinnamic aldehyde, as specified in the European Pharmacopoeia[6]. Also, it contains less than 7.5% eugenol, less than 0.5% coumarin, 0.1-1% *trans*-2-methoxy cinnamaldehyde, and less than 1% benzyl-benzoate.

CBO is a commercial product from *Cinnamomum zeylanicum* Blume with Chemical Abstracts Service (CAS) number 8015-91-6 (Sigma-Aldrich, St. Louis, MI, USA). According to the manufacturer's procedure, the *C. zeylanicum* plant was transported in polyethylene bags and dried continuously at room temperature. CBO was obtained by the hydrodistillation method. The plant material was ground into small pieces and placed in a bottle (2 L) with double distilled water (1.5 L). The mixture was boiled for 4 hours. The extract was concentrated in the cooling vapor to collect the essential oil. The extracted oil was dried with anhydrous sodium sulfate. CBO was kept at 4°C until use.

The studies of Yüce et al[14,15] were taken as a reference in determining the daily dose of 100 mg/kg CBO.

Experimental Groups

This study included 26 Sprague-Dawley female rats, 13 weeks old, weighing 206-280 grams. Rats were obtained from İnönü University Experimental Animals Center. The subjects were housed in cages (50x35x20 cm) with free access to water and food in an environment where the ambient temperature was 21±2°C, the humidity was 60±5% for 28 days, with a period of 12 hours during the day and 12 hours at night. All procedures were completed within the scope of the approval (2020/18-1) obtained from the Ethics Committee of İnönü University. The rats were simply randomized to 3 groups, 8 in the Sham group and 9 in each of the other two groups. Corn oil was used as the vehicle solution.

1. Right sciatic nerves (RSN) of rats in the Sham group were explored, and the incision was closed with 3.0 silk sutures. Only 0.5 mL of vehicle solution was administered to each rat by orogastric gavage for 28 days.
2. RSN of rats in the sciatic nerve injury (SNI) group were explored, and the injury was created by clamping them for 1 minute with an edentulous atraumatic clamp. The vehicle solution was then administered to each rat by orogastric gavage in a volume of 0.5 mL for 28 days.
3. RSN of rats in the sciatic nerve injury+cinnamon bark oil (SNI+CBO) group were explored, and the injury was created by clamping for 1 minute with an edentulous atraumatic clamp. Then, 100 mg/kg CBO, prepared freshly in corn oil daily, was administered to each rat by orogastric gavage in 0.5 mL volume for 28 days.

Inducing Sciatic Nerve Injury

The method of Korkmaz et al[16] was preferred in the selection of the experimental SNI model. Ketamine (75 mg/kg, Ketasol 10% Richter Pharma, Wels, Austria) and xylazine (8 mg/kg, Xylazinbio Bioveta, PLC, Ivanovie, Czech Republic) were administered intraperitoneally (i.p.) for anesthesia before SNI. The nerve-located skin area was shaved, and after disinfecting with 10% povidone-iodine (Betadine, Avrio Health, LP, New York, NY, USA), muscle tissues were dissected up to the sciatic nerve with an incision of approximately 4 cm. After unilateral clamping of the sciatic nerve for 1 minute, the incision was closed with 3.0 silk sutures. At the end of the 28 days, the hot plate test measured pain and nociception in animals. Rotarod and accelarod tests measured motor activity, balance, and coordination functions. Histopathological analysis was also performed with the sciatic nerve samples taken.

Rotarod/Accelerod Tests

Rotarod/Accelerod tests were performed on rats to measure motor activity, balance, and coordination. Rats were taught by repeatedly putting them on a revolving rod at the slowest speed (5 rpm) until they moved onto the rod on their own. After the rod stopped moving, the rats stayed there until the researcher removed them. Rotamex 4/8 system (Columbus Instruments International Corporation, Columbus, OH, USA) was used for both tests. In the rotarod test, the running time of the rats on the rotating shaft at constant speeds of 5, 10, 15, 20, 25, 30, and 40 rpm (maximum 5 minutes) was determined. In the accelerod test, running on the accelerated spindle from 0 rpm to 79 rpm in 4 minutes and 10 minutes was determined[17].

Hot Plate Test

On the 28th day, the rat's sense of pain and nociception were tested with the hot plate analgesimetry test. The floor temperature of the hot plate device (Columbus Instruments International Corporation, Columbus, OH, USA) was set to 50±0.5°C, and the rats' residence time on the ground was tested (cut off: 60 seconds)[18].

Histochemistry and Immunohistochemical Analysis

To evaluate histochemistry and immunohistochemical parameters, sciatic nerves were removed from rats euthanized under overdose anesthesia (225 mg/kg ketamine and 24 mg/kg xylazine, i.p.) while maintaining their integrity. Sciatic nerves extracted from rats were taken into 10% neutral buffered formalin. Tissue samples were fixed at room temperature for 24 hours. At the end of the fixation period, the tissues were washed under running tap water for 6 hours. Afterward, the samples were photographed, sized, and dissected, and the tissue was followed up. After the tissue follow-up, samples (Thermo-Excelsior ES, Cheshire, UK) were brought to the paraffin embedding station (histocenter), where they underwent the xylene, alcohol, and paraffin wax series for a total of 14 hours, respectively (Maxotech MX632, Istanbul, Turkey). They were embedded in paraffin by giving appropriate positions in order not to take longitudinal and transverse sections at the embedding station. Sections of 4 µm thickness were taken from paraffin-embedded sciatic nerve samples with a rotary microtome (Leica RM 2255, Nussloch, Germany) for immunohistochemistry (IHC) and conventional staining. Tissue sections were taken for neurofilament (NfP) and vimentin (Vmt), and IHC parameters were stained in a fully automatic staining device (Dako Omnis, Agilent, Santa Clara, CA, USA) in accordance with the guidelines. Hematoxylin and eosin (H&E) stain on tissue sections, was automatically stained with standard time and reagents with a fully automatic staining shut-off device (Leica ST 5020, Wetzlar, Germany). Special histochemistry stains luxol fast blue (LFB), masson trichrome (MsT), and phosphotungstic acid-hematoxylin (PTAH) were studied manually[19].

Determined IHC parameters; NfP (Rabbit Polyclonal, 1/500, GeneTex International Corporation, Hsinchu, T'ai-wan, Taiwan) and Vmt (Rabbit Polyclonal, 1/500, GeneTex International Corporation, Hsinchu, T'ai-wan, Taiwan) were stained on a fully automated stainer (Dako Omnis, Agilent, Santa Clara, CA, USA). The protocols and times specified in the kit manual were applied for the imaging kit reagents (Dako EnVision FLEX System, Agilent, Santa Clara, CA, USA) used in tissue IHC for both parameters. Tissues were held at high pH for 30 minutes for antigen retrieval and incubated in primary antibody for 20 minutes. In negative control, staining, phosphate buffer saline (PBS) was used instead of the primary antibody. For the positive control, rat brain tissue was co-stained on the same slide as the test tissues. Both protein expressions were shown in brown depending on the diaminobenzidine (DAB) chromogen selection. The preparations were examined and photographed with a light microscope (Olympus Bx-50, Olympus Europa SE & Co., Hamburg, Germany).

Statistical Analysis

Descriptive statistics of the data were summarized as median (minimum-maximum). While the Kruskal-Wallis test was used for independent group analysis in statistical analyses, the Wilcoxon or Friedman test was used where appropriate, depending on the number of variables for dependent group analysis. p-value <0.05 was considered statistically significant. IBM SPSS Statistics 26.0 program (IBM Corp., Armonk, NY, USA) was used in the analysis.

Results

Rat Body Weights

When the body weights of the rats at the beginning and end of the experiment were compared, the Sham group had a statistically significant difference (p<0.05) (Table I).

Table I. Body weights of rats at the beginning and end of the experiment.

	The beginning of the experiment (gram)	The end of the experiment (gram)	*p*-value*
Groups	Median (min-max)	Median (min-max)	
Sham	225.5 (209-250)	251 (231-260)	**0.025**
SNI	242 (223-266)	254 (235-270)	0.138
SNI+CBO	233 (206-280)	246 (227-285)	0.207

*: Wilcoxon test. SNI: sciatic nerve injury, CBO: cinnamon bark essential oil.

Rotarod/Accelerod Tests

The 5, 10, 15, 20, 25, 30, and 40 rpm test results of the rats in the rotarod test are presented in Table II. According to the analysis results, no significant difference was found at 5, 10, 15, and 40 rpm. A statistically significant difference was found between the SNI group and the SNI+CBO group at 20 rpm and 25 rpm ($p<0.05$). A statistically significant difference was found between the SNI group and Sham and SNI+CBO groups at 30 rpm ($p<0.05$).

In the accelerod test of the rats, the running times on the shaft accelerated from 0 rpm to 79 rpm in 4 minutes and 10 minutes are presented in Table III. According to the analysis results, a statistically significant difference was found between the SNI group with the Sham and SNI+CBO groups at the 4 minutes ($p<0.05$).

Hot Plate Test

In the hot plate test, there was a statistically significant difference between the SNI group and the Sham and SNI+CBO groups ($p<0.05$). The results are presented in Table IV.

Histochemistry and Immunohistochemical Results

All preparations in all three groups were graded by blind reading regarding pre-determined histopathology parameters. Grading was done semi-quantitatively. Both histomorphological findings, the basis for the grade, and the degrees of staining intensities were determined as 0: none, 1: weak intensity, 2: moderate intensity, 3: severe intensity. After the grading, the preparations stained with H&E, MsT, LFB, PTAH and IHC were evaluated under a light microscope, and the results obtained were noted.

Table II. Rotarod test results.

Parameters**	Groups*			*p*-value
	Sham	SNI	SNI+CBO	
5 rpm (sec)	300 (300-300)	300 (300-300)	300 (300-300)	1.000
10 rpm (sec)	300 (76-300)	300 (300-300)	300 (190-300)	0.132
15 rpm (sec)	175.5 (71-300)	239 (56-300)	246 (60-300)	0.867
20 rpm (sec)	147.5 (35-300)	69 (36-98)	183[a] (32-300)	**0.046**
25 rpm (sec)	71 (32-300)	46 (22-300)	175[a] (41-300)	**0.019**
30 rpm (sec)	46[a] (20-300)	20 (5-55)	50[a] (39-195)	**0.029**
40 rpm (sec)	25.5 (14-169)	30 (4-61)	40 (5-164)	0.433

*[a]: It is statistically different compared to the SNI group. **: The variables are summarized as median (min-max).

Table III. Accelerod test results.

Parameters**	Groups*			*p*-value
	Sham	SNI	SNI+CBO	
4 minutes 0-79 rpm (sec)	109[a] (61-140)	63 (46-103)	102[a] (67-149)	**0.044**
10 minutes 0-79 rpm (sec)	200 (145-334)	129 (106-219)	213 (112-317)	0.052

*[a]: It is statistically different compared to the SNI group. **: The variables are summarized as 'median (min-max)'.

Table IV. Hot plate test results.

Parameters**	Groups*			*p*-value
	Sham	SNI	SNI+CBO	
Hot plate test (sec)	19.73[a] (11.90-23.57)	12.60 (8.70-15.8)	19.87[a] (13.03-21.03)	**0.034**

*[a]: It is statistically different compared to the SNI group. **: The variables are summarized as median (min-max).

Sham group

It was found that all sciatic nerve, transverse and longitudinal sections in the Sham group had the appearance of normal histology, and each tissue section had similar characteristics. In H&E stained preparations, the appearance of nerve bundles packed by the perineurium surrounded by the epineurium was normal in the transverse sections of the nerve fibers. In longitudinal sections, nerve fibers were seen parallel to each other, uninterrupted, and in packages with Schwann cell (SWC) nuclei decoupled between them [Figure 1 (1A)]. The myelin sheath surrounding the axonal appendages with LFB and PTAH dyes continued normally and uninterrupted [Figure 1 (1B-1D)]. Thin endoneurial collagen surrounding the myelin sheath could easily be observed in tissue sections stained with MsT dye [Figure 1 (1C)]. When the same structures were stained with PTAH dye, they were observed to have similar properties with MsT [Figure 1 (1C-1D)]. In preparations stained by the IHC method, NfP showed intense expression with a dark brown staining pattern in Sham group sciatic nerve samples [Figures 2 (1A-1B)]. It was seen that Vmt was expressed in weak-moderate intensity with the determined grading criterion [Figure 2 (1C-1D)].

SNI group

When the longitudinal sections of the samples belonging to the SNI group were examined, edema and diffuse vacuole were observed between the parallel course of nerve fibers and marked hypertrophy in SWC. As signs of Walerian degeneration, myelin sheath deterioration, specialized macrophages, and mast cells were observed intensively [Figure 1 (2A-2C)]. When LFB-stained preparations were evaluated, a remarkable increase in mast cell count and the presence of specialized macrophages were observed, with degenerated nerve bundles and disruption of the myelin sheath clearly visible in most of the samples [Figure 1 (2B)]. MsT-stained preparations reflected the general appearance of the SNI group's sciatic nerve tissue sections. It was observed that mostly degenerated, non-continuous nerve bundles and specialized macrophages were located near myelin degeneration. A remarkable increase in mast cells and axoplasmic vacuole was noted in Figure 1 (2C). Axonal degeneration, increase in connective tissue, and degenerate SWC nuclei were noted from SNI tissue sections with PTAH dye [Figure 1 (2D)]. When IHC parameters in SNI samples were examined, it was observed that axoplasmic vacuole was dominant, and NfP was expressed at a very low level when compared to the Sham group in tissue sections with degenerative morphology and therefore showed a mild staining pattern [Figure 2 (2A-2B)]. It was observed that the expression level of Vmt was higher on a cellular basis compared to Sham group [Figure 2 (2C-2D)].

SNI+CBO group

When the sections belonging to the SNI+CBO group were examined, the first thing that attracted attention was the proliferation of SWCs and that this regeneration image was the dominant image for the samples of the SNI+CBO group [Figure 1 (3A)]. It was determined that the axoplasmic vacuole was at a moderate level, degenerated cell remnants were partially eliminated, SWCs were organized to form Bungner bands, and this organization rarely took a cylindrical appearance to form an endoneurial tube in some areas [Figure 1 (3A)][20,21]. It was noted that debris was eliminated after axonal degeneration in lateral flow dipstick (LFD) staining, and SWC again showed proliferation and reorganization [Figure 1 (3B)]. With MsT staining, it was observed that the reactive SWC was organized to surround the myelin, as well as a significant increase in endoneurial collagen [Figure 1 (3C)]. In the sciatic nerve tissue sections where PTAH dye was applied, it was found that the degenerate SWC nuclei, which were seen extensively in the SNI group, were not included in the SNI+CBO group, and vacuole formation was significantly reduced. It was noted that the

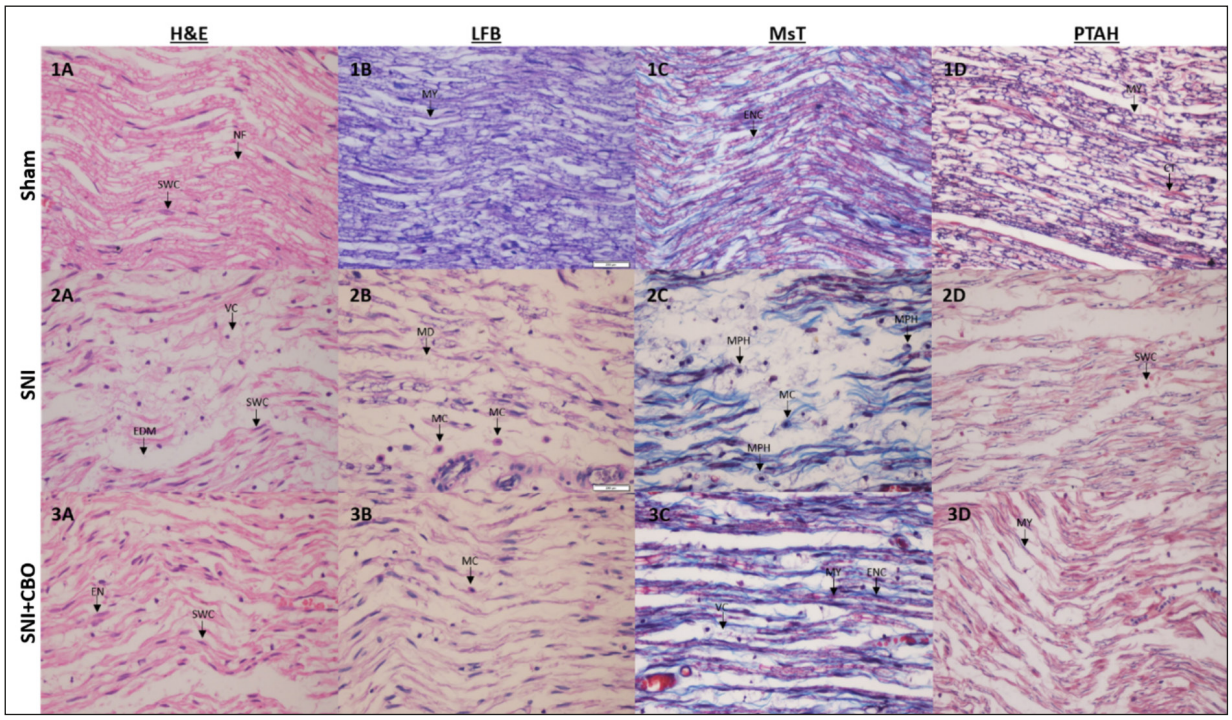

Figure 1. **1A**, normal histology in view of the longitudinal sections of the sciatic nerve, the nerve fibers (NF) are bundled, parallel, wavy, uninterrupted, and in bundles with SWC (SWC) nuclei H&E ×400. **1B**, The myelin sheath (MY) surrounding the axonal appendages in normal appearance LFB ×400. **1C**, Thin endoneurial collagen (ENC) enveloping the myelin sheath in normal histological appearance MsT ×400. **1D**, Myelin sheath (MY), and connective tissue (CT) surrounding axonal appendages PTAH ×400. **2A**, Interruptions in nerve fiber continuity, edema (EDM), diffuse vacuole (VC), pronounced hyperthorphia in SWC H&E ×400. **2B**, Degeneration of the myelin sheath (MD), the number of mast cells that attract attention (MC) LFB ×400. **2C**, Obvious collagen fiber increase, degenerative nerve bundles and disruption of the myelin sheath, the presence of mast cells (MC) and specialized macrophage (MPH) MsT ×400. **2D**, Axonal degeneration, ligament increase, and degenerate SWC nuclei PTAH ×400. **3A**, Proliferation and regeneration of SWC (SWC). The appearance of the endoneurial tube (EN) formed by medium-level axoplasmic vacuole and SWC H&E ×400. **3B**, Debris has been eliminated after degeneration, proliferation in regenerated SWC, sparse mast cell (MC) LFB ×400. **3C**, Reactive SWC and reduced image of endoneurial collagen (ENC), axoplasmic vacuole (VC) surrounding myelin (MY) MsT ×400. **3D**, Degenerate SWC nuclei, seen extensively in SNI groups' sciatic nerve samples, are not included in the SNI+CBO group. Reappearing myelin (MY) sheath PTAH ×400.

myelin sheath progressed decently between the regenerated SWC bands. Due to the IHC parameters, the SNI+CBO group compared to the other two groups; although NfP was at a lower level compared to the Sham group, it was found that it was expressed at a significantly higher level in the SNI group and a moderate intensity brown staining pattern was formed. The expression level of Vmt was found to be at the highest level in the SNI+CBO group compared to the Sham and SNI groups.

When the groups were compared in terms of myelin sheath degeneration, there was a statistically significant difference between the Sham group and the SNI and SNI+CBO groups ($p<0.05$). When the groups were compared in terms of myelin sheath degeneration, there was a statistically significant difference between the SNI group and the SNI+CBO group ($p<0.05$). There was a statistically significant difference between the Sham group and the SNI and SNI+CBO groups when the groups were evaluated in terms of macrophage cells ($p<0.05$). There was a statistically significant difference between the SNI group and the SNI+CBO group when the groups were compared in terms of macrophage cells ($p<0.05$). When the groups were contrasted in terms of mast cells, the Sham group and the SNI and SNI+CBO groups showed a statistically significant difference ($p<0.05$). The Sham group and the SNI and SNI+CBO groups showed significant differences when the groups were compared for the edema in the perineurium ($p<0.05$). The SNI group and the SNI+CBO group showed a

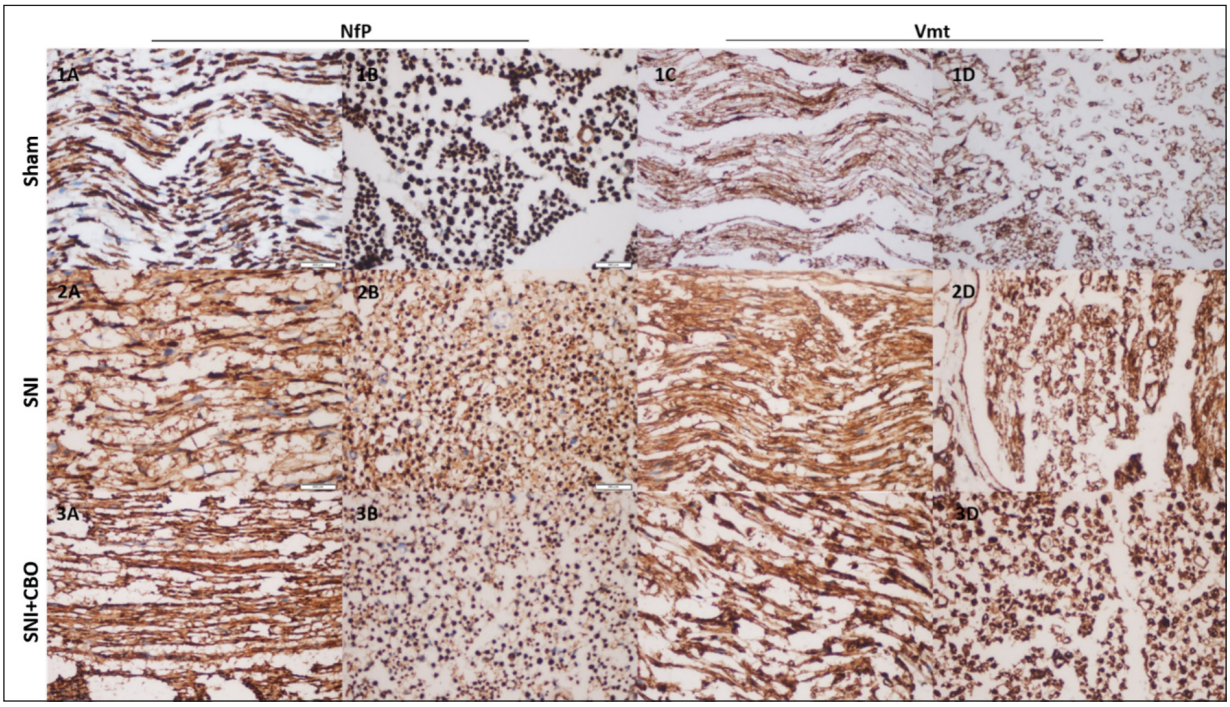

Figure 2. **1A-1B**, Expression intensity with the dark brown staining pattern was shown in longitudinal (1A) and transverse (1B) sections of Sham group sciatic nerve samples NfP ×400. **1C-1D**, A weak-moderate intensity staining pattern was observed in the Sham group compared to the other groups Vmt ×400. **2A-2B**, Poor staining pattern in tissue sections where axoplasmic vacuole is dense NfP ×400. **2C-2D**, Moderate expression and staining pattern on a cellular basis compared to the Sham group Vmt ×400. **3A-3B**, Lower protein expression compared to the Sham group but higher in SNI group NfP ×400. **3C-3D**, The staining pattern shows the highest level of expression in the SNI+CBO group compared to the Sham and SNI groups Vmt ×400.

statistically significant difference in the edema in the perineurium when the groups were compared ($p<0.05$). There was a statistically significant difference between the Sham group and the SNI and SNI+CBO groups when the groups were examined in terms of axonal degeneration ($p<0.05$). There was a statistically significant difference between the SNI group and the SNI+CBO group when the groups were evaluated for axonal degeneration ($p<0.05$). The Sham group and the SNI and SNI+CBO groups showed a statistically significant difference when the groups were compared in terms of the axoplasmic vacuole ($p<0.05$). There was a statistically significant difference between the SNI group and the SNI+CBO group when the groups were compared in terms of the axoplasmic vacuole ($p<0.05$). There was a statistically significant difference between the Sham group and the SNI and SNI+CBO groups when the groups were evaluated in terms of neurofilament ($p<0.05$). Vmt comparisons across the groups revealed a statistically significant difference between the Sham group and the SNI and SNI+CBO groups ($p<0.05$). There was a statistically significant difference between the SNI group and the SNI+CBO group when the groups were compared in terms of Vmt ($p<0.05$) (Table V).

Discussion

The current study aimed to investigate the effect of CBO with proven antioxidant and anti-inflammatory effects on sciatic nerve damage in rats.

Peripheral nerves can be damaged by thermal, chemical, and mechanical causes. Conditions such as traffic accidents, stab wounds, and gunshot wounds can cause nerve damage. However, the most common cause of damage is trauma. Peripheral nerve damage occurs in 2.8% of trauma patients, many of which result in long-term loss of function[22]. In addition to trauma-related conditions, intramuscular injections in the gluteal region, penetrating trauma, contusion, hip fracture surgery, and nerve compression can occur. Gunshot wounds, lacerations, femoral shaft

Table V. The differences between the groups were graded according to the parameters given in the table.

Parameters**	Groups*			*p*-value
	Sham	SNI	SNI+CBO	
Myelin sheath degeneration	$0^{a,b}$ (0-0)	3^{b} (2-3)	1 (0-2)	< 0.001
Macrophage	$0^{a,b}$ (0-0)	2^{b} (2-3)	1 (0-1)	< 0.001
Mast cell	$0^{a,b}$ (0-0)	1 (0-2)	1 (0-1)	0.003
Edema in the perineurium	$0^{a,b}$ (0-0)	1.5^{b} (1-2)	1 (0-1)	< 0.001
Axonal degeneration	$0^{a,b}$ (0-0)	2^{b} (2-3)	1 (0-1)	< 0.001
Axoplasmic vacuole	$0^{a,b}$ (0-0)	2^{b} (2-2)	1 (1-1)	< 0.001
Neurofilament	$3^{a,b}$ (3-3)	1 (1-2)	2 (1-3)	< 0.001
Vimentin	$1.5^{a,b}$ (1-2)	2^{b} (2-3)	3 (2-3)	0.002

*: Variables are summarized as median (min-max). **: [a]: It is statistically different compared to the SNI group. [b]: It is statistically different compared to the SNI+CBO group.

fractures, contusions, penetrating trauma, and iatrogenic injuries are the most prevalent causes that can induce sciatic nerve injury in the thigh region[4,5]. According to the study by Foster et al[23] in 2018, sciatic nerve injuries constitute 16.6% of peripheral nerve injuries.

Injury to the peripheral nerves may leave functional or morphological flaws. Nevertheless, after spontaneous regeneration in the distal nerve section, a restoration to function could be seen. Surgery is seldom favored over pharmaceutical therapy. According to experimental research, many pharmacological treatments have successfully treated nerve damage[11,13,16].

The preventive and regenerative effects of neuroactive steroids have been shown in experimental models of degeneration after physical damage to peripheral nerves. Indeed, following nerve transection, neuroactive hormones boost the expression of the *P0* gene. For instance, therapy with progesterone or dihydroprogesterone dramatically raises the low messenger levels of *P0* in the rat sciatic nerve's distal section near the incision[24]. The same steroids also reverse the changes brought on by crush-induced degeneration. For instance, nerve-crushed mice treated with progesterone or dihydroprogesterone showed enhanced nociception, increased myelin protein expression, and restored function of the Na^{+}-K^{+}-ATPase pump[25]. Iwaoka et al[26] reported that cinnamaldehyde in cinnamon selectively stimulates progesterone secretion in human adrenal cells.

Beji et al[27], in an experimental diabetic rat model, found that cinnamon compounds exert an antioxidant effect by increasing the levels of enzymes such as glutathione peroxidase, catalase, and superoxide dismutase. Studies[28,29] have reported that cinnamon's phenolic and flavonoid compounds have potent antioxidant effects. According to their research, Gulcin et al[29] stated that the active compounds in cinnamon could provide a hydrogen atom to free radicals that have an unpaired electron in their outer orbit, making them stable and consequently reducing the oxidative stress in the cell and protecting it from apoptosis.

According to Li et al[30], cinnamaldehyde, the major compound in CBO, has been shown to be antiproliferative with pro-apoptotic effects. Cinnamaldehyde is protective against cancer due to oxidative stress by inducing apoptosis through different mechanisms. Cinnamaldehyde increases caspase-9 and caspase-3 enzyme activity by increasing cytochrome C release from mitochondria. In addition, while it increases the expression of pro-apoptotic factors such as the *B-cell lymphoma 2 (Bcl-2) associated X (Bax)* gene, *Bcl-2* stimulates apoptosis in the cell by decreasing the expression of apoptotic inhibitors. Long et al[31], as another mechanism, cinnamaldehyde activates nuclear factor erythroid 2-related factor (Nrf2) protein, which is the primary regulator of the cellular antioxidant defense system. They showed that by blocking this effect of ubiquitin, *Nrf2* gene expression increased the half-life of the Nrf2 protein. This activation leads to the release of antioxidant enzymes and protects the cell from oxidative stress. Ranasinghe et al[32] and Elgendy et al[33] reported that eugenol and CBO showed potent antioxidant activity in inhibiting peroxynitrite-induced lipid peroxidation.

There are studies[34] showing that balance, motor activity, and coordination decrease in rats

due to sciatic nerve damage. Therefore, the rotarod and accelerod tests were used in the present investigation to evaluate various motor impairment characteristics. Motor activity, balance, and coordination functions of the rats were evaluated in the rotarod and accelerod tests. In the rotarod test, significant differences were observed between the group in which CBO was applied at 20, 25, and 30 rpm and the group in which only vehicle solution was applied. Significant differences were observed between CBO+SNI and SNI groups in the accelerod test. The significant results of the rotarod-accelerod tests showed that SNI rats performed their motor coordination tasks for a shorter period than the Sham and SNI+CBO groups.

The hot plate test is the most used experimental technique for determining nociception in rats[35]. Drugs that cause antinociception on the hot plate test and those used to treat pain clinically have a strong correlation. In our study, we evaluated pain and nociception in the rats using the hot plate test. According to the current hot plate test findings, CBO had more antinociceptive effects than the Sham and SNI groups. In the study of Vissers et al[36], a rat's sciatic nerve was applied with four loose ligatures, resulting in chronic constriction injury (CCI), which causes a pronounced hypersensitivity to both non-noxious stimulation and chemical irritants. However, a formalin injection in the hind paw of a rat with CCI-induced mononeuropathy led to a reduction in ipsilateral flinching and licking or biting behavior in both stages of the formalin testing. Comparatively to sham and unoperated animals, this changed behavior was accompanied by lower adrenocorticotropic hormone and corticosterone plasma levels. Only in the second phase of the formalin test, formalin injection in the contralateral nonligated hind paw of CCI rats similarly decreased the licking or biting behavior compared to sham-operated and non-operated control animals. CCI decreases the sensitivity to pain and the hypothalamic-pituitary-adrenal axis activation to ipsilateral and contralateral formalin injection. Acute pain reactions are marked by elevated glucocorticoids, but chronic pain is not. This finding suggests that the hypothalamic-pituitary-adrenal axis has undergone particular alterations that prevent the persistent nature of chronic pain from raising baseline glucocorticoid levels. According to the study published by Hidayat et al[37] in 2022, in the serum of rats given cinnamon extract, there was a reduction in the corticotropin-releasing hormone, adrenocorticotropin hormone, and corticosterone levels.

Peripheral nerves are frequently susceptible to physical harm (such as cutting, crushing, or trapping with nerve compression), which may result in a type of peripheral degeneration that can be categorized based on the severity of the nerve injury. A condition called Wallerian degeneration happens when a nerve is crushed or severed. As a result, the portion of the axon distal to the damage degenerates, with myelin disintegration and involvement of macrophages and SWC[38,39]. According to the histology literature, it was observed that the section samples taken from all sciatic nerve samples in the Sham group had a normal histological appearance, and each tissue section had similar characteristics. Edema between nerve fibers, diffuse vacuole, marked hypertrophy in SWC, and myelin sheath disruption, a sign of Wallerian degeneration, and intense observation of specialized macrophages and mast cells, observed in the SNI group, clearly indicate nerve damage. The absence of nuclei of degenerated SWC observed in the SNI+CBO group, a marked decrease in vacuole formation, and a regular progression of the myelin sheath along the nerve were observed. According to the observed results, CBO has a positive effect on the histological process of sciatic nerve injuries.

In a study published by Qabaha et al[40] in 2017, they showed that cinnamon inhibits the release of proinflammatory cytokines and that cinnamic acid in it significantly reduces interleukin-6 and Tumor necrosis factor-α (TNF-α) levels. Schink et al[41] determined that *trans*-cinnamaldehyde and *p*-cymene compounds in cinnamon have strong anti-inflammatory effects and show these effects by synergistically reducing interleukin-8 secretion. They also reported that cinnamon and its main component, cinnamaldehyde, exert an anti-inflammatory effect by decreasing the release of pro-inflammatory factors such as inducible nitric oxide synthase (iNOS), cyclooxygenase-2 (COX-2), TNF-α, protein kinase B, mitogen-activated protein kinase (MAPK) and nitric oxide (NO) synthesis *via* the nuclear factor kappa-B (NF-*κ*B) pathway.

In comparison to CNS axons, PNS axons show a remarkable capacity for regeneration following damage. Nevertheless, injury-induced nerve gaps prevent the regeneration of PNS axons. Long-distance regeneration is also impossible because the environment required for the development of

PNS axons is not maintained over time. As a result, studying psychoneuroimmunology could aid in PNS regeneration and CNS injury recovery. Successful axon regeneration requires a strong regenerative response from the wounded neuron and the coordinated activities of non-neuronal cells that produce extracellular matrix components, cytokines, and growth factors that promote axon regrowth. Axonal disintegration in the distal nerve stump triggers the inflammatory response by permeabilizing the blood-nerve barrier and activating surrounding SWC and local macrophages through receptors sensitive to tissue injury. In response to damage, denervated SWCs multiply, phagocytose debris, shed myelin, and release cytokines that attract blood-borne monocytes and macrophages. During days post-psychoneuroimmunology, macrophages take up the majority of phagocytosis before leaving the nerve through the bloodstream after remyelination. The PNS's effectiveness contrasts sharply with the CNS's, where the response of adjacent cells is linked to inhibitory scar development, quiescence, and degeneration/apoptosis. By producing toxic proinflammatory mediators for a more extended period of time, macrophages invading the brain worsen cell death and damage rather than effectively eliminating debris before ending the inflammatory response as in other tissues. The cinnamon fraction's polyphenolic composition was examined using chromatography and mass spectrometry, and the results showed that phenolic acids, flavonoids, and procyanidins were made up of the cinnamon fraction. Gaudet et al[42] demonstrated that the cinnamon fraction dose-dependently inhibited interleukin-6, interleukin-8, and TNF-α production using a macrophage model primed with lipopolysaccharides. The capacity of the fraction to stop lipopolysaccharide-induced NF-κB activation may be the cause of this suppression of cytokine release, according to the evidence presented. It was revealed that mast cells and macrophages increased in the SNI group and decreased in the SNI+CBO group.

In this study, longitudinal slices of samples from the SNI group are examined, edema and diffuse vacuoles are seen between parallel nerve fiber courses, and SWC exhibit pronounced hypertrophy. Specialized macrophages and mast cells as indicators of Walerian degeneration and myelin sheath degradation were closely scrutinized. When the sections from the SNI+CBO group were inspected, the first thing that stood out was the proliferation of SWC, and this regeneration picture dominated the samples from the SNI+CBO group. It was found that SWCs were organized into Bungner bands, the axoplasmic vacuole was at a moderate level, degenerated cell remnants were largely removed, and this organization seldom assumed a cylindrical shape to create an endoneurial tube in specific locations. After axonal degeneration, LFD labeling revealed that debris had been removed, and SWC once again displayed proliferation and rearrangement. Using MsT dye, endoneurial collagen increased significantly; however, it was discovered that it was arranged to surround the reactive SWC and myelin.

The findings of the Jahromi et al[43] research suggested that cinnamaldehyde might hasten the healing of the sciatic nerve after crush damage. Cinnamaldehyde had more favorable effects on myelin content, muscle mass ratio, and sciatic functional index recovery. The study showed that cinnamaldehyde favorably impacted peripheral nerve regeneration. Cinnamaldehyde therapy might thus be considered a viable therapeutic approach for peripheral nerve regeneration and functional rehabilitation. Our results showed that the degree of edema in the perineurium, axonal degeneration, and axoplasmic vacuole increased in the SNI group and decreased in the SNI+CBO group. In tissue sections with degenerative morphology, it was shown that axoplasmic vacuole was prominent, and NfP was expressed at a very low level as compared to the Sham group. NfP expression was observed to be considerably greater in the SNI+CBO group compared to the other two groups, even if it was present at a lower level than in the Sham group, resulting in the formation of a moderately intense brown staining pattern.

To analyze the myelin and NfP content in a model of sciatic nerve crush injury, Fowler et al[44] were able to determine the amounts of myelin and neurons by staining for myelin protein zero and NfP. This histological examination showed different degrees of myelin and NfP damage that were severity dependant. The findings also showed unique damage evolution patterns for myelin and neurons. Their research exposes the early patterns of damage progression and the status of two important nerve components, myelin, and neurons, immediately after injury. In our study, longitudinal and transverse slices of NfP-positive sciatic nerve samples from the Sham group had an intense expression pattern with dark brown staining. Tissue slices with

dense NfP axoplasmic vacuoles exhibit poor staining patterns. Reduced protein expression in the SNI group NfP compared to the Sham group, although greater.

A significant type III intermediate filament protein called Vmt is involved in several fundamental cellular processes, including cell migration, proliferation, and division. Vmt is a cytoplasmic protein but is also present at the cell surface and extracellular matrix. Vmt may have a variety of physiological effects in various disorders and traumas of the nervous system, according to earlier research. For instance, developing reactive astrocytes is the primary focus of investigations on Vmt in spinal cord injury and stroke[45]. Compared to the Sham group and the SNI group, the SNI+CBO group was shown to have the most significant expression level of Vmt.

Conclusions

Our study findings revealed the beneficial effects of CBO in rats with sciatic nerve damage. Further research must be done on this essential oil's use in treating nerve injury.

Conflict of Interest

The Authors declare that they have no conflict of interests.

Ethics Approval

Complied with the "Animal Experiments: Notice of In Vivo Trials: ARRIVE Guidelines" standards to improve the quality and transparency of animal experimentation research[46]. All procedures were completed within the scope of the approval (2020/18-1) obtained from the Ethics Committee of İnönü University.

Funding

This research is supported by a research grant from the Scientific and Technological Research Council of Türkiye (Project number: 1919B012002540 belongs to S.F. Izci).

Authors' Contribution

O. Ozhan: conception, design, supervision, materials, data collection and/or processing, analysis and/or interpretation, literature review, writing, critical review. S.F. Izci: conception, design, fundings, materials, data collection and/or processing, analysis and/or interpretation, literature review, writing. M. Huz: materials, data collection and/or processing, analysis and/or interpretation, literature review, writing. M. Colak: materials, data collection and/or processing, analysis and/or interpretation. Z. Kucukakcali: materials, data collection and/or processing, analysis and/or interpretation. H. Parlakpinar: conception, design, supervision, materials, data collection and/or processing, analysis and/or interpretation, literature review, writing, critical review.

Availability of Data and Materials

All data generated or analyzed during this study are included in this article. Further inquiries can be directed to the corresponding author.

Informed Consent

Not applicable.

ORCID ID

O. Ozhan: 0000-0001-9018-7849
S. F. Izci: 0009-0005-5896-718X
M. Huz: 0000-0003-4474-256X
M.Colak: 0000-0003-0896-4990
Z. Kucukakcali: 0000-0001-7956-9272
H. Parlakpinar: 0000-0001-9497-3468.

References

1) Asplund M, Nilsson M, Jacobsson A, von Holst H. Incidence of traumatic peripheral nerve injuries and amputations in Sweden between 1998 and 2006. Neuroepidemiology 2009; 32: 217-228.
2) Rosberg HE, Carlsson KS, Cederlund RI, Ramel E, Dahlin LB. Costs and outcome for serious hand and arm injuries during the first year after trauma - a prospective study. BMC Public Health 2013; 13: 501.
3) Kim DH, Murovic JA, Tiel R, Kline DG. Management and outcomes in 353 surgically treated sciatic nerve lesions. J Neurosurg 2004; 101: 8-17.
4) Seddon HJ. A classification of nerve injuries. Br Med J 1942; 2: 237-239.
5) Kline DG, Kim D, Midha R, Harsh C, Tiel R. Management and results of sciatic nerve injuries: a 24-year experience. J Neurosurg 1998; 89: 13-23.
6) Council of Europe (Strasbourg), Convention on the elaboration of a European pharmacopoeia, Council of Europe. European Department for the Quality of Medicines, European Directorate for the Quality of Medicines & Healthcare, & European Pharmacopoeia Commission. European Pharmacopoeia: Published in Accordance with the Convention on the Elaboration of a European Pharmacopoeia (European Treaty Series No. 50) 2010; Council of Europe.
7) Chen YF, Wang YW, Huang WS, Lee MM, Wood WG, Leung YM, Tsai HY. Trans-cinnamaldehyde, an essential oil in cinnamon powder, ameliorates cerebral ischemia-induced brain injury via inhibition of neuroinflammation through attenuation

of iNOS, COX-2 expression and NFκ-B signaling pathway. Neuromolecular Med 2016; 18: 322-333.

8) Escop, & European Scientific Cooperative on Phytotherapy. ESCOP Monographs: the scientific foundation for herbal medicinal products. George Thieme Verlag, 2003.

9) Singh G, Maurya S, DeLampasona MP, Catalan CA. A comparison of chemical, antioxidant and antimicrobial studies of cinnamon leaf and bark volatile oils, oleoresins and their constituents. Food Chem Toxicol 2007; 45: 1650-1661.

10) Chericoni S, Prieto JM, Iacopini P, Cioni P, Morelli I. In vitro activity of the essential oil of Cinnamomum zeylanicum and eugenol in peroxynitrite-induced oxidative processes. J Agric Food Chem 2005; 53: 4762-4765.

11) Durak MA, Ozhan O, Tetik B, Yildiz A, Aksungur Z, Vardi N, Turkoz Y, Ucar M, Parlakpinar H. Effects of apocynin on sciatic nerve injury in rabbits. Biotech Histochem 2023; 98: 172-178.

12) Luo L, Yang JX, Luo T, Liu D, Wu GH, He JM. A study on the mechanism of PP2A in the recovery of SCI in rats through downregulation of MMP-9 via MAPK signaling pathway. Eur Rev Med Pharmacol Sci 2021; 25: 7195-7203

13) Atilgan N, Duman N, Colak TS, Korucu IH, Demiryurek M. Multidisciplinary treatment and functional outcome evaluation of combined injuries of nerves, vessels, and flexor tendons: spaghetti wrist. Eur Rev Med Pharmacol Sci 2022; 26: 8808-8815.

14) Yüce A, Türk G, Çeribaşı S, Güvenç M, Çiftçi M, Sönmez M, Özer Kaya Ş, Çay M, Aksakal M. Effectiveness of cinnamon (Cinnamomum zeylanicum) bark oil in the prevention of carbon tetrachloride-induced damages on the male reproductive system. Andrologia 2014; 46: 263-272.

15) Yüce A, Türk G, Çeribaşi S, Sönmez M, Çiftçi M, Güvenç M. Effects of cinnamon (Cinnamomum zeylanicum) bark oil on testicular antioxidant values, apoptotic germ cell and sperm quality. Andrologia 2013; 45: 248-255.

16) Korkmaz MF, Parlakpinar H, Erdem MN, Ceylan MF, Ediz L, Samdanci E, Kekilli E. The therapeutic efficacy of dexpanthenol on sciatic nerve injury in a rat model. Br J Neurosurg 2020; 34: 397-401.

17) Yucel A, Aydogan MS, Parlakpinar H, Erdogan MA, Kurt A, Ucar M, Durmus M. Effects of propofol and dexmedetomidine on motor coordination and analgesia: a comparative analysis. Int J Clin Pharmacol Ther 2012; 50: 678-682.

18) Erdogan MA, Polat A, Yucel A, Aydogan MS, Parlakpinar H, Tekin S, Durmus M, Ozcan Ersoy M. Effects of perineural administration of dexmedetomidine in combination with levobupivacaine in a rat sciatic nerve block. Curr Ther Res Clin Exp 2013; 74: 74-78.

19) Luna L. Armed forces institute of pathology manual of histological staining methodsed. McGraw-Hill, New York, NY, USA; 1968.

20) Jessen KR, Mirsky R. The success and failure of the schwann cell response to nerve injury. Front Cell Neurosci 2019; 13: 33.

21) Panzer KV, Burrell JC, Helm KVT, Purvis EM, Zhang Q, Le AD, O'Donnell JC, Cullen DK. Tissue engineered bands of büngner for accelerated motor and sensory axonal outgrowth. Front Bioeng Biotechnol 2020; 8: 580654.

22) Noble J, Munro CA, Prasad VS, Midha R. Analysis of upper and lower extremity peripheral nerve injuries in a population of patients with multiple injuries. J Trauma 1998; 45: 116-122.

23) Foster CH, Karsy M, Jensen MR, Guan J, Eli I, Mahan MA. Trends and cost-analysis of lower extremity nerve injury using the national inpatient sample. Neurosurg 2019; 85: 250-256.

24) Melcangi RC, Magnaghi V, Galbiati M, Ghelarducci B, Sebastiani L, Martini L. The action of steroid hormones on peripheral myelin proteins: a possible new tool for the rebuilding of myelin? J Neurocytol 2000; 29: 327-339.

25) Roglio I, Bianchi R, Gotti S, Scurati S, Giatti S, Pesaresi M, Caruso D, Panzica GC, Melcangi RC. Neuroprotective effects of dihydroprogesterone and progesterone in an experimental model of nerve crush injury. Neurosci 2008; 155: 673-685.

26) Iwaoka Y, Hashimoto R, Koizumi H, Yu J, Okabe T. Selective stimulation by cinnamaldehyde of progesterone secretion in human adrenal cells. Life Sci 2010; 86: 894-898.

27) Beji RS, Khemir S, Wannes WA, Ayari K, Ksouri R. Antidiabetic, antihyperlipidemic and antioxidant influences of the spice cinnamon (Cinnamomum zeylanicumon) in experimental rats. Braz J Pharm Sci 2018; 54: e17576.

28) Singh N, Rao AS, Nandal A, Kumar S, Yadav SS, Ganaie SA, Narasimhan B. Phytochemical and pharmacological review of Cinnamomum verum J. Presl-a versatile spice used in food and nutrition. Food Chem 2021; 338: 127773.

29) Gulcin I, Kaya R, Goren AC, Akincioglu H, Topal M, Bingol Z, Cetin Çakmak K, Ozturk Sarikaya SB, Durmaz L, Alwasel S. Anticholinergic, antidiabetic and antioxidant activities of cinnamon (Cinnamomum verum) bark extracts: polyphenol contents analysis by LC-MS/MS. Int J Food Prop 2019; 22: 1511-1526.

30) Li J, Teng Y, Liu S, Wang Z, Chen Y, Zhang Y, Xi S, Xu S, Wang R, Zou X. Cinnamaldehyde affects the biological behavior of human colorectal cancer cells and induces apoptosis via inhibition of the PI3K/Akt signaling pathway. Oncol Rep 2016; 35: 1501-1510.

31) Long M, Tao S, De La Vega MR, Jiang T, Wen Q, Park SL, Zhang DD, Wondrak GT. Nrf2-dependent suppression of azoxymethane/dextran sulfate sodium-induced colon carcinogenesis by the cinnamon-derived dietary factor cinnamaldehyde. Cancer Prev Res 2015; 8: 444-454.

32) Ranasinghe P, Pigera S, Premakumara GA, Galappaththy P, Constantine GR, Katulanda P.

Medicinal properties of 'true' cinnamon (Cinnamomum zeylanicum): a systematic review. BMC Complement Altern Med 2013; 13: 275.

33) Elgendy EM, Ibrahim HS, Elmeherry HF, Sedki AG, Mekhemer FU. Chemical and biological comparative in vitro studies of cinnamon bark and lemon peel essential oils. Food Sci Nutr 2016; 8: 110-125.

34) Korkmaz MF, Parlakpınar H, Ceylan MF, Ediz L, Şamdancı E, Kekilli E, Sağır M. The effect of sildenafil on recuperation from sciatic nerve injury in rats. Balkan Med J 2016; 33: 204-211.

35) Arabzadeh E, Rahimi A, Zargani M, Simorghi Z, Emami S, Sheikhi S, Amirani Z, Yousefi P, Sarshin A, Aghaei F, Feizolahi F. Resistance exercise promotes functional test via sciatic nerve regeneration, and muscle atrophy improvement through GAP-43 regulation in animal model of traumatic nerve injuries. Neurosci Lett 2022; 787: 136812.

36) Vissers K, Adriaensen H, De Coster R, De Deyne C, Meert TF. A chronic-constriction injury of the sciatic nerve reduces bilaterally the responsiveness to formalin in rats: a behavioral and hormonal evaluation. Anesth Analg 2003; 97: 520-525.

37) Hidayat R, Wulandari P, Reagan M. The potential of cinnamon extract (Cinnamomum burmanii) as anti-insomnia medication through hypothalamus pituitary adrenal axis improvement in rats. Acta Med Acad 2022; 51: 79-84.

38) Bramley JC, Collins SV, Clark KB, Buchser WJ. Avian axons undergo Wallerian degeneration after injury and stress. J Comp Physiol A Neuroethol Sens Neural Behav Physiol 2016; 202: 813-822.

39) Rosenberg AF, Wolman MA, Franzini-Armstrong C, Granato M. In vivo nerve-macrophage interactions following peripheral nerve injury. J Neurosci 2012; 32: 3898-3909.

40) Qabaha K, Abu-Lafi S, Al-Rimawi F. Anti-inflammatory activities of ethanolic extracts of Curcuma longa (turmeric) and cinnamon (Cinnamomum verum). J Food Nutr Res 2017; 5: 668-673.

41) Schink A, Naumoska K, Kitanovski Z, Kampf CJ, Fröhlich-Nowoisky J, Thines E, Pöschl U, Schuppan D, Lucas K. Anti-inflammatory effects of cinnamon extract and identification of active compounds influencing the TLR2 and TLR4 signaling pathways. Food Funct 2018; 9: 5950-5964.

42) Gaudet AD, Popovich PG, Ramer MS. Wallerian degeneration: gaining perspective on inflammatory events after peripheral nerve injury. J Neuroinflammation 2011; 8: 110.

43) Jahromi Z, Mohammadghasemi F, Moharrami Kasmaie F, Zaminy A. Cinnamaldehyde enhanced functional recovery after sciatic nerve crush injury in rats. Cells Tissues Organs 2020; 209: 43-53.

44) Fowler X, DeHority RL, Geary M, Elfar JC. Analysis of myelin and neurofilament content in a sciatic nerve crush injury model. J Nat Sci 2015; 1: 166.

45) Chen KZ, Liu SX, Li YW, He T, Zhao J, Wang T, Qiu XX, Wu HF. Vimentin as a potential target for diverse nervous system diseases. Neural Regen Res 2023; 18: 969-975.

46) McGrath JC, Drummond GB, McLachlan EM, Kilkenny C, Wainwright CL. Guidelines for reporting experiments involving animals: the ARRIVE guidelines. Br J Pharmacol 2010; 160: 1573-1576.