

Gastroprotective effect of earthworm paste (*Lampito mauritii*, Kinberg) on experimental gastric ulcer in rats

M. PRAKASH, G. GUNASEKARAN

Department of Zoology, Annamalai University, Annamalainagar, Tamil Nadu (India)

Abstract. – Background: For thousands of years, earthworm and its products have been used for its therapeutic benefits. The traditional medical knowledge of indigenous people throughout the world more particularly in Asia, including India, Myanmar, China, Korea and Vietnam has played vital role in identifying, extracting and using biologically active compounds from earthworms.

Materials and Methods: Effect of various doses (20, 40, 80, 160 and 320 mg/kg, po) of earthworm paste (*Lampito mauritii*, Kinberg) was studied on aspirin-induced gastric ulcer and compared to ranitidine.

Results: The earthworm paste showed significant ulcer protective effects. The cytoprotective effect of the earthworm paste seems to be not only due to the anti-secretory action but also to the effects on mucosal glycoprotein. The decrease in total acidity, pepsin and protein content of the gastric juice proved the antiulcer activity of earthworm paste. Histopathological studies revealed that the earthworm paste was more effective in gastric cytoprotection than ranitidine in preventing lesion formation.

Conclusions: These observations show that the earthworm paste possess antiulcer potential.

Key Words:

Earthworm, *Lampito mauritii*, Aspirin, Anti-ulcer.

Introduction

The organic and functional dyspepsia are common clinical syndromes characterized by pain associated with the stomach. Organic dyspepsia can be caused by peptic ulcer disease, a common gastro-intestinal disorders in clinical practice. The increase in acid-pepsin secretion and decrease in mucosal resistance appears to be the basic causes for peptic ulceration. The aetiology of gastric ulcer is mainly due to defective mucosal

resistance. Although the cause of ulceration is not known, gastric acid and pepsin are responsible for maintaining the lesion, once it is produced¹. The mucosal resistance is lowered by the *Helicobacter pylori*-gram negative bacillus that colonizes the stomach and duodenum. Aspirin a non-steroidal anti-inflammatory drug which induces the peptic ulcer causes increase in gastric secretion, reduces the pH leads to acidity which damages the epithelial cells and sub mucosa layer. Davenport² suggested first that the normal resistance of the gastric mucosa to back diffusion of luminal acid can be disrupted by topical administration of lipid soluble damaging agents such as acetylsalicylic acid or aspirin. Oral administration of aspirin has the ability to transform the gastric mucosa rapidly from a hydrophobic to a more hydrophilic state³.

Over the last 25 years, a remarkable revolution in the pathophysiology and treatment of gastric and duodenal ulcers have occurred. Several therapies that have been successful in healing peptic ulcers include neutralizing gastric acid, inhibiting acid secretion and protecting the gastro duodenal mucosa. Efforts are being made to discover a effective anti-ulcerogenic drug which will not only heal the ulcer but also prevent its recurrence. Search for a suitable drug for the treatment of ulcer from natural products is an ongoing process. Considering the several side effects of modern medicine, indigenous drugs possessing fewer side effects should be looked for as a better alternative for the treatment of ulcer.

Earthworms, a soil macro-invertebrate possess many therapeutic role is recorded in many ancient literature and they are used still in countryside for numerous ailments. For a long period of time, earthworms have been a valuable source of natural products for maintaining human health, especially in India, China and most of the Asian countries. Earthworm derivatives have been used as

drugs against various diseases in China and the Far East for a few thousand years. Earthworms have been used in medicine for various remedies since 1340 A.D.⁴ and their medicinal properties have been described by Bristowf⁵. According to the description given by Vohora and Khan⁶ earthworms have largely been used internally and externally as powerful aphrodisiacs. Mihara et al.⁷ and Ismail et al.⁸ reported that earthworm has the potentiality in the treatment of thrombosis and in fact, orally administered earthworm powder was capable of digesting intravascular fibrin clots. Bhatnagar and Palta⁹ reported that earthworms ingested into our body system increase body heat and are of value in neurologic disorders, bronchitis, tuberculosis and holding a substance effective in curing rheumatism. Recently earthworm protein and its coelomic fluid are known to have cytolytic, agglutination, proteolytic, haemolytic, mitogenic, anti-pyritic, tumorstatic, anti-inflammatory and antibacterial activities¹⁰⁻¹⁸. Earthworm tonic is also used for balancing the sympathetic and parasympathetic functions of the central nervous system. In Korea taking "earthworm soup" before going to bed is a traditional habit, which enriches general health and prevents various ailments. Earthworm is formulated as "earth dragon" by allergy research group and used as a suitable drug for the gastro-intestinal disorders caused in gastro-intestinal tract. Hence in the present study efforts have been made to find the anti-ulceral property of earthworm paste compared with a reference drug ranitidine in rats.

Materials and Methods

Preparation of Earthworm Paste

Earthworms *Lampito mauritii* (Kinberg) were obtained from the stock culture, Division of Vermibiotechnology, Department of Zoology, Annamalai University, Tamil Nadu, India. 500 sexually mature, clitellate worms (900 mg/worm) were washed with running tap water and then fed with wet blotting paper for 18-20 hours for gut clearance. The gut cleared worms were again washed with distilled water. The worms were kept in plastic trough covered tightly with polythene cover and exposed to sunlight for three days to kill the earthworms. Mucus and coelomic fluid that oozed out from the worms digested the dead worms forming a brown coloured paste called "earthworm paste".

Animals Used

Healthy and pure strain male albino rats (*Rattus norvegicus*), ranging from the body weight of 150-200 gm were procured from the Department of Experimental Medicine, Central Animal House, Rajah Muthiah Medical College, Annamalai University, Annamalainagar and used for the experimental study. The animals were housed in polypropylene cages at 24°C ± 2°C and were fed with proper food and water ad libitum throughout the experiment. The experiment got clearance from the Institutional Animal Ethical Committee (IAEC).

Drugs

Aspirin, "earthworm paste" and standard drug ranitidine were suspended in 1% carboxy methyl cellulose before experiment and given orally for 10 days during the experiment.

Aspirin Plus Pyloric Ligation Induced Ulcer Model

The methods of Goel et al.¹⁹, Shay et al.²⁰ and Parmar²¹) were followed for the evaluation of anti-ulceral activity. The animals were divided into 8 groups of 6 animals each. Out of 8 groups, group I served as normal control and received water. Group II served as aspirin control receiving aspirin (200 mg/kg). The remaining 6 groups served as treated groups receiving ranitidine (50 mg/kg) – a standard drug and "earthworm paste" administered in different doses (20, 40, 80, 160 and 320 mg/kg). All the doses were administered orally once daily for 10 days. From the 6th day onwards, animals in groups III to VIII received aspirin (200 mg/kg) orally, one hour after the administration of the earthworm paste was done. On the 11th day pylorus ligation was carried out on the 18 hours fasted rats.

Collection and Analysis of Gastric Juice

Gastric juice was collected by a 4 h pyloric ligation²⁰. Normal rats and those from experimental groups were anaesthetized with ether and cut open through a midline incision in the abdomen. The pylorus was secured and ligated with silk sutures after which the wound was closed and the animals allowed to recover. Drinking water was withheld for 4 h. The rats were then killed by an overdose of chloroform vapours. The stomach was removed after clamping the oesophagus and the gastric contents were collected. The gastric juice was centrifuged at 3500 rpm for 15 min. Aliquots from this was used for the assay of

pepsin²² and total protein²³. Total acidity was determined by titrating with 0.01N sodium hydroxide using phenolphthalein as indicator.

Histopathological Studies

The stomach was washed with normal saline and fixed in Bouin's fluid. After 24 hours the tissues were processed following standard techniques²². Sections of 6 thickness were stained in Heidenhain's haematoxylin and counterstained with eosin for microscopic observation.

Statistical Analysis

Results are expressed as means \pm SD. Statistical analysis was done using Students t-test. A value of $P < 0.05$ was considered significant.

Results

Gastric Secretion

The total acidity, pepsin activity and protein content of the gastric juice of normal and experimental animals are presented in Table I. The aspirin-ulcerated rats showed significantly higher pepsin activity, protein content and total acidity as compared to normal rats. Rats pretreated with earthworm paste and ranitidine showed a significantly lower activity of pepsin, protein content and total acidity of gastric juice compared to the ulcerated group. Particularly 160 mg/kg of earthworm paste shows better reduction in pepsin, protein content and total acidity of gastric juice when compared to the ranitidine treated animal.

Histopathological Observations

The histopathology of stomach of aspirin treated animals showed ulceration with haemorrhage and discontinuity in the mucosal epithelial lining.

The aspirin induced ulcer model shows various changes in the histopathological architecture of the stomach. The aspirin induced gastric lesion is multifactorial with the depletion of gastric wall mucous content. The gastric mucosa or the mucous membrane is damaged thereby producing ulcer, the mucosal layer was severely affected by the administration of aspirin. The blood vessels in the mucosal layer were damaged. Venular constriction were found to be observed in the epithelial cells of mucous membrane. Pretreatment with 50 mg/kg ranitidine was found to reduce the occurrence of gastric lesion (Figure 3). There was lesser ulcer in the gastric mucosa. The intensity of haemorrhage was significantly reduced upon the pretreatment with ranitidine. The mucosal necrosis of the gastric epithelium was found to be reduced. Sub-mucosal venular constrictions in the epithelial cells were reduced. Similarly no gastric lesions were observed in the animals treated with earthworm paste. Treatment with 160 mg of earthworm paste/kg was found to show better results than the ranitidine treated animals (Figure 7). This was followed by 80 mg/kg (Figure 6), 320 mg/kg (Figure 8) and 40 mg/kg (Figure 5) treatments. But 20 mg of earthworm paste/kg (Figure 4) had the least effect.

Discussion

In general ulcers were caused by the back diffusion of H⁺ ions into the mucosal cells²⁵. The histopathological observations on the ulcer in the stomach induced by aspirin revealed gastric lesions, damage to mucosal epithelium, blood ves-

Table I. Effect of pretreatment with different doses of earthworm paste and ranitidine on the total acidity, and protein content in aspirin-treated rats (*Rattus norvegicus*) ($P < 0.05$).

Treatments	Total acidity ^a	Pepsin activity ^b	Protein ^c
Normal control	15.29 \pm 0.27	1.36 \pm 0.4	0.995 \pm 0.1
Aspirin induced ulcer control	53.15 \pm 0.17*	3.01 \pm 0.2*	4.25 \pm 0.2*
Standard drug (Ranitidine 50 mg/kg)	24.68 \pm 0.16**	1.95 \pm 0.1**	1.27 \pm 0.3
Earthworm paste (mg/kg) 20	33.17 \pm 0.40**	2.99 \pm 0.5**	3.51 \pm 0.1**
40	30.60 \pm 0.54**	2.42 \pm 0.2**	2.72 \pm 0.4**
80	22.39 \pm 0.21**	2.01 \pm 0.3**	2.15 \pm 0.2**
160	20.09 \pm 0.41**	1.75 \pm 0.6**	1.25 \pm 0.3**
320	29.30 \pm 0.29**	2.07 \pm 0.4**	2.20 \pm 0.4**

Values are means \pm SD from six rats in each group. *Compared to normal $P < 0.05$; **compared with aspirin treated $P < 0.05$
^aExpressed as mEq/l; ^bExpressed as μ g tyrosine liberated/mg protein/h; ^cExpressed as mg/ml.

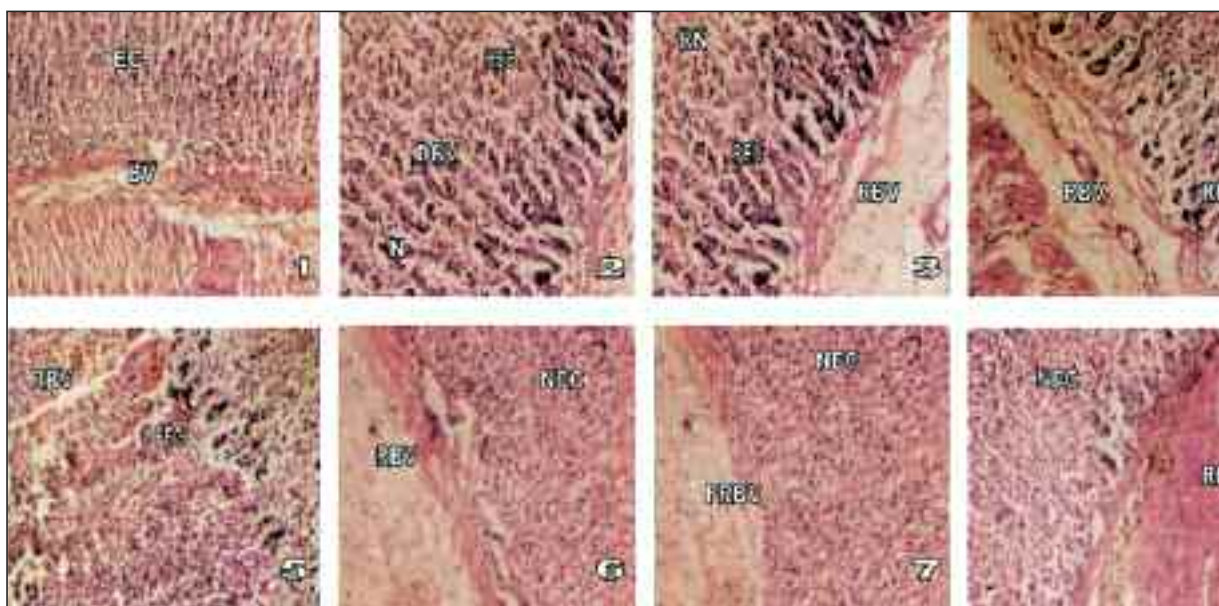


Figure 1-1. Section of normal stomach showing normal epithelial cells (EC) and blood vessels (BV). (Magnification 400 ×).
Figure 1-2. Section of aspirin induced ulcerated stomach showing necrosis (N), damaged blood vessels (DBV) and haemorrhage and discontinuity in epithelial cells (HEC). (Magnification 400 ×).
Figure 1-3. Section of standard drug ranitidine treated stomach showing regained necrosis (RN), packed and continuity in epithelial cells (PEC) and regained blood vessels (RBV). (Magnification 400 ×).
Figures 1-4 and 1-5. Section of 20 and 40 mg earthworm paste/kg treated rats shows regained blood vessels (RBV), regained necrosis (RN) and packed and continuity in epithelial cells (PEC). (Magnification 400 ×).
Figure 1-7. Section of 160 mg earthworm paste/kg treated rats shows normalized epithelial cell (NEC) and fully regained blood vessels (FRBV). (Magnification 400 ×).
Figures 1-6 and 1-8. Section of 80 and 320 mg earthworm paste/kg treated rat shows normalized epithelial cells (NEC) and regained blood vessels (RBV). (Magnification 400 ×).

sels and constriction in the veins. These damages were found to be prevented by the pretreatment with the standard drug-ranitidine and treatment with different doses of earthworm paste.

Ulcerogens like ACTH, cortisone, ethanol, aspirin and phenylbutazone reduce the rate of secretion of mucus and reduce the concentration of protein bound carbohydrates in the secretion²⁶. These agents injure the gastric mucosa by reducing its ability to form a protective layer of mucus. In addition, the ACTH and cortisone decrease the rate of renewal of surface epithelial cells while aspirin and phenylbutazone increases the rate of exfoliation of surface epithelial cells²⁷. Aspirin induces gastric lesion (ulcer) by causing back diffusion of H^+ ions into the mucosal cells²⁵. The ethanol or aspirin induced gastric lesions are multifactorial with the depletion of gastric wall mucus content²⁸. Mucosal blood flow has also been attributed to be an important factor in the damage caused by non-steroidal anti-inflammatory drugs (NSAIDs) and is modu-

lated by prostaglandin²⁹. Submucosal venular constriction by NSAIDs drugs and eventual injury is caused to perturbations of superficial mucosal cells³⁰. Aspirin causes leakage of plasma protein into gastric juice. This reflects the increased protein concentration in the gastric juice of aspirin control rats. In the present study pretreatment with earthworm paste decreases the protein concentration in the gastric juice, their by preventing the plasma membrane from the damage. The administration of 200 mg/kg of aspirin had induced gastric ulcer by producing mucosal damage, gastric lesion, constriction in epithelial cells and decrease in number of cells. Sanmugapriya et al.²⁷ suggested that the presence of polyphenolic compounds prevents damages to the gastric mucosa. Some flavonoids have been shown to increase the mucosal content of prostaglandin and mucus in gastric mucosa, showing their cytoprotective effects^{31,32} suggested that pretreatment of ambrex (a herbomineral formulations) on ethanol induced

damages reduced the gastric lesion and haemorrhage. Falling in line with the above observations in the present study, the pretreatment with earthworm paste had reduced the gastric lesions, increased in number of epithelial cells and reduced the mucosal damage. This may be due to the presence of polyphenolic compounds in earthworm tissue and SH group containing aminoacids, which prevents the gastric damage by increasing the mucin activity¹⁰. The effect of earthworm paste against gastric ulcer is much better than the ranitidine treatment. Particularly treatment with 160 mg earthworm paste/kg showed better cure than ranitidine. The antiulcer effect of the earthworm paste may be due to the formation of mucin like gel layer on the surface of the mucosa or via the formation of protecting complexes between gel and mucus as a barrier against the agents introduced into the stomach or against endogenously formed acid and pepsin in the stomach. The histopathological observations showed that upon earthworm paste treatment, the mucosal epithelium had retained normal histoarchitecture, less haemorrhage and more significant on reduction in ulcer which proves the anti-ulcer activity.

References

- 1) BHATTACHARYA SK, SEN P, RAY A, DAS PK. Pharmacology and Pharmacotherapeutics. Popular Prakasham Publishers, Mumbai, 2004.
- 2) DAVENPORT HW. Gastric mucosal injury by fatty and acetyl-salicylic acids. J Gastroenterol 1964; 46: 245-253. Gastric mucosal haemorrhage in dogs—Effect of acid, aspirin and alcohol. J Gastroenterol 1969; 56: 439.
- 3) LICHTENBERGER LM, WANG ZM, ROMERO JJ, ULLOA C, PEREZ JC, GIRAUD MN, BARRETO JC. NSAIDs associate with zwitterionic phospholipids: Insight into the mechanism and reversal of NSAID-induced gastrointestinal injury. Nat Med 1995; 1: 154-158.
- 4) STEPHENSON J. In Oligochaeta. Clarendon Press Oxford, 1930, pp. 658.
- 5) BRISTOWF HS. Insects and other invertebrates for human consumption in Siam. Trans Entomol Soc (London) 1932; 80: 387-404.
- 6) VOHORA SB, KHAN MSY. Animal Origin Drugs Used in Unani Medicine. Institute of History of Medicine and Medical Research, Tughlaqabad, New Delhi, 1978, 137.
- 7) MIHARA H, SUMI H, YONETA T, MIZUMOTO H, IKEDA R, SEIKI M, MARUYAMA M. A novel fibrinolytic enzyme extracted from the earthworm *Lumbricus rubellus*. Japanese J Physiol 1991; 41: 461-472.
- 8) ISMAIL SA, PULANDIRAN K, YEGNANARAYAN R. Anti-inflammatory activity of earthworm extracts. Soil Biol Biochem 1992; 24: 1253-1254.
- 9) BHATNAGAR RK, PALTA RK. Earthworm vermiculture and vermicomposting. Kalyani Publishers, New Delhi, 2002.
- 10) EDWARDS CA, BOHLEN PJ. Biology and ecology of earthworms. Third Edition, Chapman and Hall, London, 1996.
- 11) LANGE S, NUBLER F, KAUSCHKE G, LUTSCH G, COOPER EL, HERRMANN A. Interaction of earthworm hemolysin with lipid membranes requires sphingolipids. J Biol Chem 1997; 271: 20884-20892.
- 12) POPOVIC M, MIHAELA THR, BABI T, KOS J, GRDISA MA. Effect of earthworm (G-90) extract on formation and lysis of clots originated from venous blood of dogs with cardiopathies and with malignant tumors. Pathol Oncol Res 2001; 7: 197-202.
- 13) LIU Y, SUN Z, WANG S, LI LIU Y. Purification of a novel antibacterial short peptide in earthworm *Eisenia foetida*. Acta Biochem Biophysica Sinica 2004; 36: 297-301.
- 14) EDWARDS CA. Earthworm Ecology, St. Lucie Press, DC, 2004.
- 15) COOPER EL. CAM eCAM, Bioprospecting: The 21st century Pyramid. Evidence Based Comp Ancient Med 2005; 2: 125-127.
- 16) POPOVIC M, GRDISA MA, HRZENJAK TM. Glycolipoprotein G-90 obtained from the earthworm *Eisenia foetida* exerts antibacterial activity. Vet Arch 2005; 75: 119-128.
- 17) PRAKASH M, BALAMURUGAN M, PARTHASARATHI K, GUNASEKARAN G, COOPER EL, RANGANATHAN LS. Anti-ulcer and antioxidative properties of earthworm paste of *Lampito mauritii* on *Rattus norvegicus*. Eur Rev Med Pharmacol Sci 2007; 11: 9-15.
- 18) PRAKASH M, GUNASEKARAN G, ELUMALAI K. Effect of earthworm powder on antioxidant enzymes in alcohol induced hepatotoxic rats. Eur Rev Med Pharmacol Sci 2008; 12: 237-243.
- 19) GOEL RK, CHAKRABARTI A, SANYAL AK. The effect of biological variables on the antiulcerogenic effect of vegetables plantain banana. Planta Medica 1985; 2: 85-88.
- 20) SHAY M, KAMAROV SA, FELS D, MERANZE D, GRUENSTEIN H, SIPLET H. A simple method for the uniform production of gastric ulceration in the rats. J Gastroenterol 1945; 5: 43-61.
- 21) PARMAR ED. Upper gastrointestinal hemorrhage. Thomas. Springfield, Illinois. 1970, p. 257.
- 22) ANSON ML, MIRSKY AE. The estimation pepsin with hemoglobin. J Gen Physiol 1933; 16: 59-63.

- 23) LOWRY OH, ROSEBROUGH NJ, FARR AL, RANDALL RJ. Protein measurement with the Folin-Phenol reagent. *J Biol Chem* 1951; 193: 265-275.
- 24) GURR E. *Methods of analytical histology and histochemistry*. Leonard Hidd (Book) Ltd., London, 1958.
- 25) PARMAR ED. 1970. *Upper gastrointestinal hemorrhage*. Thomas. Springfield, Illinois. 1970, p. 257
- 26) BOCKUS HL. *Gastroenterology*, W.B. Saunders's Company, Philadelphia, USA, 1963.
- 27) SANMUGAPRIYA E, SHANMUGASUNDARAM P, VENKATARAMAN S. Antiulcerogenic effect of *Justica Prostrata* Gamble. *Indian J Exp Biol* 2005; 43: 181-186.
- 28) AL-HARBI MM, QUERSHI S, RAZA M, AHMED M, AFZAL M, SHAH AH. Gastric antiulcer and cytoprotective effect *Commiphora molmol* in rats. *J Ethnopharmacol* 1997; 55: 141-150.
- 29) HOLLANDER D, TARANAWSKI A, GERGELY H, ZIPSER KD. Sucralfate protection of the gastric mucosa against alcohol induced injury: A prostaglandin mediated process. *Scand J Gastroenterol* 1984; 191: 97-102.
- 30) VANISREE AJ, MITRA K, SHYMALA DEVI CS. Antiulcerogenic effect of UL-409 against experimentally induced gastric ulcer in rats. *Indian J Pharmacol* 1996; 28: 265-268.
- 31) KONTUREK SJ. Antiulcer and gastroprotective effects of solon, a synthetic flavonoid derivatives of sophoradin: role of endogenous prostaglandins. *Eur J Pharmacol* 1986; 125: 185.
- 32) NARAYAN S, DEVI RS, JAINU M, SABITHA KE, SHYMALA DEVI CS. Protective effect of a polyherbal drug, ambrex in ethanol-induced gastric mucosal lesions in experimental rats. *Indian J Pharmacol* 2004; 36: 34-37.